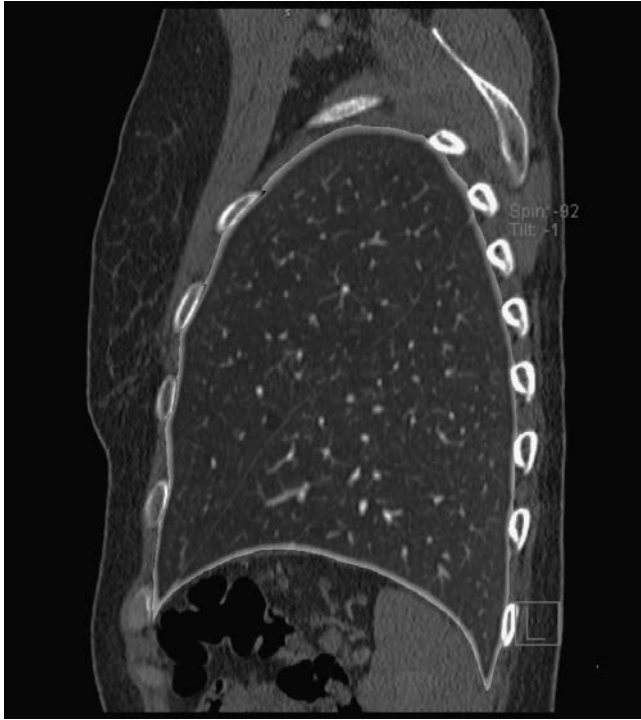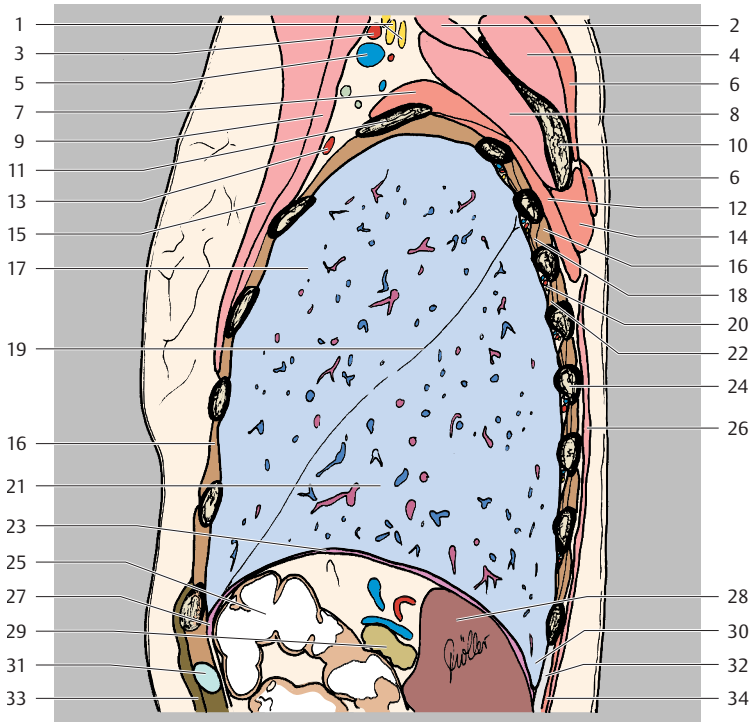
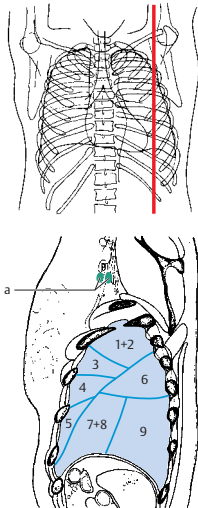

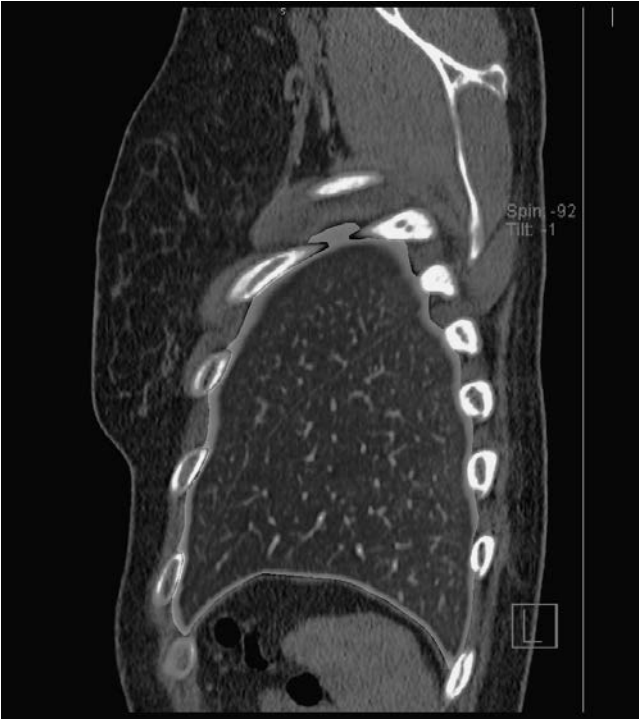
- 1+2 Apicoposterior segment of upper lobe
- 3 Anterior segment of upper lobe
- 4 Superior lingular segment of upper lobe
- 5 Inferior lingular segment of upper lobe
- 6 Superior segment of lower lobe
- 7+8 Medial basal (cardiac) + anterior basal segments of lower lobe
- 9 Lateral basal segment of lower lobe
- 10 Posterior basal segment of lower lobe

● = Lymph node (see inside back cover)  
 — = Borders of lung segments

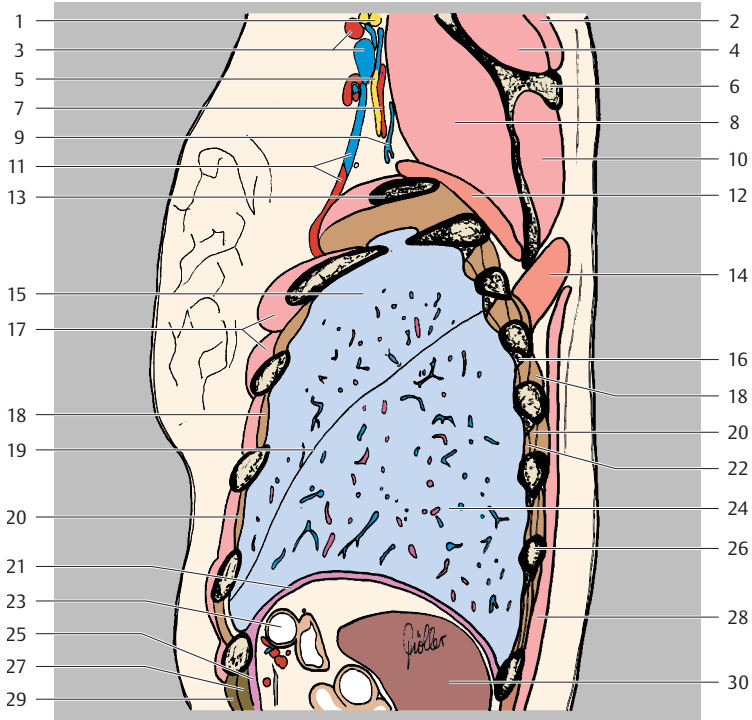


- |    |                                    |    |   |
|----|------------------------------------|----|---|
| 1  | Brachial plexus                    | 19 | Oblique fissure   |
| 2  | Levator scapulae muscle            | 20 | Intercostal vein, artery, and nerve   |
| 3  | Left subclavian artery             | 21 | Left lung (lower lobe)  |
| 4  | Supraspinatus muscle               | 22 | Innermost intercostal muscle  |
| 5  | Left subclavian vein               | 23 | Diaphragm   |
| 6  | Trapezius muscle                   | 24 | Rib 7 (posterior part)  |
| 7  | Serratus anterior muscle           | 25 | Transverse colon  |
| 8  | Subscapularis muscle               | 26 | Latissimus dorsi muscle   |
| 9  | Pectoralis minor muscle            | 27 | Greater omentum   |
| 10 | Scapula (medial border)            | 28 | Spleen  |
| 11 | Rib 2                              | 29 | Pancreas  |
| 12 | Serratus posterior superior muscle | 30 | Costodiaphragmatic recess   |
| 13 | Thoraco-acromial artery            | 31 | Rib 8 (costal cartilage)  |
| 14 | Rhomboid major muscle              | 32 | Longissimus thoracis muscle and iliocostalis lumborum muscle (part of erector spinae muscle, lateral tract) |
| 15 | Pectoralis major muscle            | 33 | Rectus abdominis muscle   |
| 16 | External intercostal muscle        | 34 | Serratus posterior inferior muscle  |
| 17 | Left lung (upper lobe)             |    |   |
| 18 | Internal intercostal muscle        |    |   |

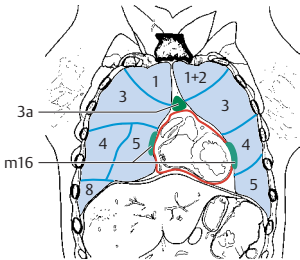
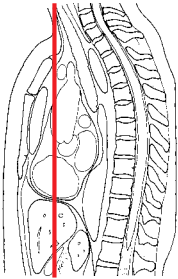
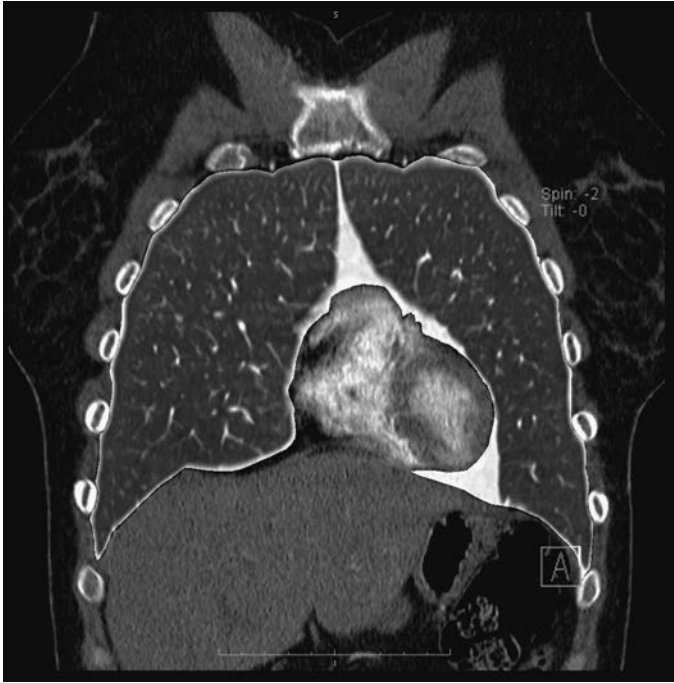


- 1+2 Apicoposterior segment of upper lobe
- 3 Anterior segment of upper lobe
- 4 Superior lingular segment of upper lobe
- 5 Inferior lingular segment of upper lobe
- 6 Superior segment of lower lobe
- 7+8 Medial basal (cardiac) + anterior basal segments of lower lobe
- 9 Lateral basal segment of lower lobe

● = Lymph node (see inside back cover)  
— = Borders of lung segments



- |    |                                  |    |                                     |
|----|----------------------------------|----|-------------------------------------|
| 1  | Brachial plexus                  | 16 | Intercostal vein, artery, and nerve |
| 2  | Trapezius muscle                 | 17 | Pectoralis major muscle             |
| 3  | Left subclavian artery and vein  | 18 | External intercostal muscle         |
| 4  | Supraspinatus muscle             | 19 | Oblique fissure                     |
| 5  | Subscapular nerve                | 20 | Internal intercostal muscle         |
| 6  | Spine of scapula                 | 21 | Diaphragm                           |
| 7  | Circumflex scapular artery       | 22 | Innermost intercostal muscle        |
| 8  | Subscapularis muscle             | 23 | Transverse colon                    |
| 9  | Circumflex scapular vein         | 24 | Left lung (lower lobe)              |
| 10 | Infraspinatus muscle             | 25 | Transversus abdominis muscle        |
| 11 | Lateral thoracic artery and vein | 26 | Rib 9 (posterior part)              |
| 12 | Serratus anterior muscle         | 27 | Internal oblique muscle             |
| 13 | Rib 3                            | 28 | Latissimus dorsi muscle             |
| 14 | Rhomboid major muscle            | 29 | External oblique muscle             |
| 15 | Left lung (upper lobe)           | 30 | Spleen                              |



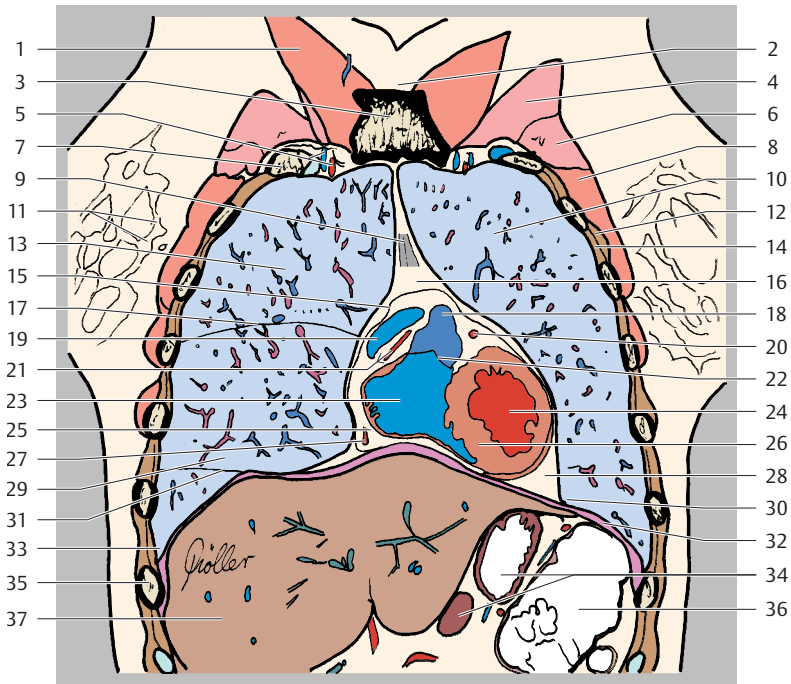
Right Lung

- 1 Apical segment of upper lobe
- 3 Anterior segment of upper lobe
- 4 Lateral segment of middle lobe
- 5 Medial segment of middle lobe
- 8 Anterior basal segment of lower lobe

Left lung

- 1+2 Apicoposterior segment of upper lobe
- 3 Anterior segment of upper lobe
- 4 Superior lingular segment of upper lobe
- 5 Inferior lingular segment of upper lobe

- = Lymph node (see inside back cover)
- = Borders of lung segments
- = Pericardium



- |    |   |    |  |
|----|---|----|--|
| 1  | Sternocleidomastoid muscle                        | 20 | Left coronary artery (interventricular branch) |
| 2  | Suprasternal notch                                | 21 | Right coronary artery in coronary sulcus       |
| 3  | Sternum (manubrium)                               | 22 | Pulmonary valve                                |
| 4  | Pectoralis major muscle                           | 23 | Right ventricle                                |
| 5  | Internal thoracic artery and vein                 | 24 | Left ventricle                                 |
| 6  | Pectoralis minor muscle                           | 25 | Subepicardial fat                              |
| 7  | Rib 1 (bony and cartilaginous parts)              | 26 | Interventricular septum                        |
| 8  | Serratus anterior muscle                          | 27 | Right coronary artery                          |
| 9  | Sternopericardial ligaments                       | 28 | Mediastinal fat                                |
| 10 | Left lung (upper lobe)                            | 29 | Right lung (middle lobe)                       |
| 11 | Parenchyma of right breast                        | 30 | Phrenicmediastinal recess                      |
| 12 | External intercostal muscle                       | 31 | Oblique fissure                                |
| 13 | Right lung (upper lobe)                           | 32 | Diaphragm                                      |
| 14 | Internal intercostal muscle                       | 33 | Costodiaphragmatic recess                      |
| 15 | Pericardium                                       | 34 | Stomach  |
| 16 | Anterior mediastinum                              | 35 | Rib 7 (bony part)                              |
| 17 | Horizontal fissure                                | 36 | Colon (left flexure)                           |
| 18 | Right ventricular outflow tract (pulmonary trunk) | 37 | Liver  |
| 19 | Right atrial appendage (auricle)                  |    |  |