

- The previously marked site of entry in the intercostal space is palpated with the index and middle finger of one hand.
- Between the two fingers a syringe with 20 mL of 2% lidocaine attached to a small-bore needle (25 or 27 gauge, ½ inch) for intradermal injection produces a small wheal (approx. 0.2 mL).
- The local anesthetic is infiltrated subcutaneously and in the intercostal muscle down to the parietal pleura, using a larger needle (0.8 or 0.9 mm). The path of the needle should be kept perpendicular to the chest wall to ensure that the entire path of the instruments will be pain free. This deeper anesthetic should only be injected after the plunger has been withdrawn partially to ensure that the needle has not penetrated a vascular structure.
- As the needle penetrates the parietal pleura, the patient usually experiences transient pain. Entry into the pleural cavity is confirmed by drawing back on the syringe, which will fill with air or pleural fluid (when aspirating pleural fluid, it is advisable to change the needle and syringe because of the risk of implanting tumor cells in the chest wall).
- The depth, established as a result of withdrawing the needle until the gas bubbles are no longer obtained, later serves as an indication for placement of the trocar.
- At this location of the parietal pleura, about 8–10 mL of lidocaine is infiltrated. Subsequently, the caudal rim of the upper rib is infiltrated to anesthetize the intercostal nerve as well as the periosteum of the rib itself, while taking care, again by repeated aspiration, that the tip of the needle is not located in the adjacent intercostal artery.
- A further lidocaine depot of about 8–10 mL is then injected around the cranial rim of the lower rib.
- Apnea is very rarely encountered.
- When the patient snores in a deep sleep due to relaxation of the pharyngeal muscles, it is sufficient to pull the lower jaw toward the front to clear the airways, or if necessary, insert a pharyngeal cannula.
- Arrhythmia: a few extra systolic beats may be noted when the pericardium is touched.
- Mediastinal shift: when air is injected (under pressure) into the hemithorax, the amplitude of ECG tracing will vary with respiratory movements. The operator should decompress the hemithorax.
- At the end of the procedure the lung should be very slowly expanded back to the chest wall by gentle negative pressure suction.
- For recovery (see “Antagonists” in **Table 11.1**), the patient can be immediately woken with flumazenil, a benzodiazepine antidote. However, since flumazenil has a shorter action than that of midazolam, there is a risk of the patient going back to sleep with the need for reinjection of flumazenil in the recovery room. Morphine is reversed by naloxone.
- Observation in the recovery room is obligatory as for any anesthetized patient. Continuous oxygenation can be titrated down according to need. The intravenous line is maintained for the next few hours until the patient is fully awake.
- It is mandatory to prescribe a postoperative analgesia.

Additional Technical Suggestions

- Local anesthesia is administered with care for each site of entry with 1% or 2% lidocaine (optionally with epinephrine when there are no cardiovascular contraindications).
- Maneuvers that are known to cause the most pain (in particular insufflation of talc) require a preventive injection of morphine.
- Monitoring results of cardiac rate, blood pressure, and respiratory rate are noted at least every 5 minutes. SaO₂ is continuously monitored and nasal oxygen is provided as needed.
- The procedure may cause hypoxia for several reasons: depression due to the anesthesia, healthy lung in the lateral decubitus position, and collapse of the investigated lung due to the induced pneumothorax.
- Most frequently, agitation and coughing may interfere with the procedure; additional morphine will help with this problem.
- The physician and assistant clean their hands with the standard surgical scrub technique and then put on a sterile gown and gloves. Every patient is monitored with automated blood pressure monitoring and cardiac and cutaneous oxygen saturation monitors. The patient’s skin is prepared by shaving and disinfecting a large area to include from the sternum to the clavicle and across the axilla past the scapula to the spinous processes and down to the base of the thorax. Then the patient is covered with sterile sheets. Usually, the thoracoscopist faces the patient during the procedure (but may change the position if needed), while the assistant is across the table. Then the following steps are taken:
 - With a scalpel, a vertical incision is made through the skin and subcutaneous tissue, appropriate to the size of the trocar tube used, usually of approximately 10 mm, parallel with and in the middle of the selected intercostal space (**Fig. 11.23**).
 - The incision is relatively small so that the trocar fits tightly and bleeding from the incision is automatically stopped due to the resulting compression.
 - The handle of the trocar should be held firmly in the palm of the hand, while the extended index finger, for safety’s sake, limits the depth of insertion previously established with the local anesthetic needle.

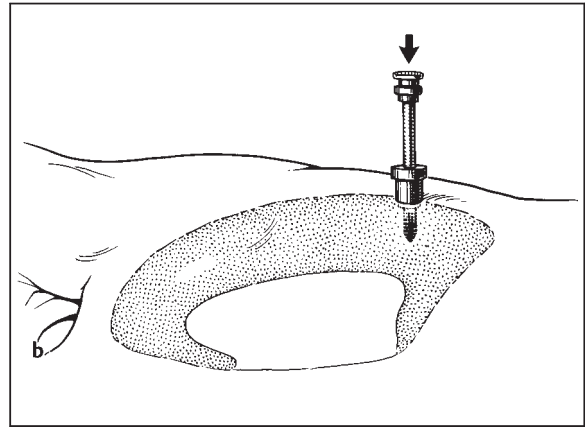
Performance of Rigid Thoracoscopy

The physician and assistant clean their hands with the standard surgical scrub technique and then put on a sterile gown and gloves. Every patient is monitored with automated blood pressure monitoring and cardiac and cutaneous oxygen saturation monitors. The patient’s skin is prepared by shaving and disinfecting a large area to include from the sternum to the clavicle and across the axilla past the scapula to the spinous processes and down to the base of the thorax. Then the patient is covered with sterile sheets. Usually, the thoracoscopist faces the patient during the procedure (but may change the position if needed), while the assistant is across the table. Then the following steps are taken:

- With a scalpel, a vertical incision is made through the skin and subcutaneous tissue, appropriate to the size of the trocar tube used, usually of approximately 10 mm, parallel with and in the middle of the selected intercostal space (**Fig. 11.23**).
- The incision is relatively small so that the trocar fits tightly and bleeding from the incision is automatically stopped due to the resulting compression.
- The handle of the trocar should be held firmly in the palm of the hand, while the extended index finger, for safety’s sake, limits the depth of insertion previously established with the local anesthetic needle.

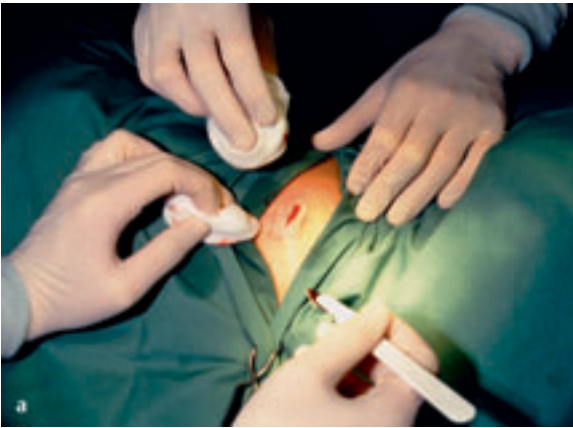

Fig. 11.23 Skin incision after local anesthesia, usually approximately 10 mm, parallel with and in the middle of the selected intercostal space (a). The trocar being placed in the pleural cavity (b).



(From P. Mathur in Beamis JF Jr, Mathur PN, eds. *Interventional pulmonology*. New York: McGraw-Hill; 1999. Reprinted with kind permission from McGraw-Hill.)

- Under difficult conditions, the needle should be left in the thorax so that the trocar can be introduced parallel to it. This is particularly helpful if the patient is restless, with resulting movement between skin and intercostal space.
- While fixating the intercostal space with two fingers, the trocar is advanced in a corkscrew motion until the sudden release of resistance is felt.
- Optional: Blunt dissection is performed with a hemostat through the intercostal muscles and parietal pleura.
- The process is identical to inserting a chest tube, with the exception that a tunnel is not created as this would limit the mobility of the thoracoscope.
- Optional: Once the parietal pleura is opened the index finger should examine the pleural cavity and confirm an adequate pleural space.
- Alternatively, the adequate size of the pleural space (and the presence of possible adhesions) can be confirmed by fluoroscopy during the pneumothorax induction (Fig. 11.14).
- Once the trocar is in the pleural cavity (Fig. 11.23b), the operator can hear the movement of air into and out of the pleural cavity synchronously with the patient's breathing.
- Pressure equilibrium with the atmosphere is established quickly.
- The cannula should lie 1–3 cm within the pleural cavity and be held in position by the assistant. If the trocar is not handled carefully, it might injure the lung.
- If the patient coughs, the assistant will withdraw the cannula within the chest wall, since the cough may have been induced by touching the lung.
- After removal of the trocar, the thoracoscope with a 0° angle is placed in the cannula (Fig. 11.24). After removal of the optic, the valve closes and this again results in a closed pneumothorax. This is particularly important in patients with effusion since otherwise pleural fluid

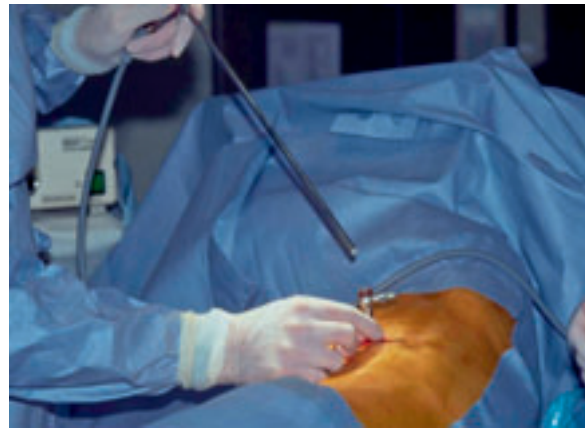

Fig. 11.24 Introduction of the rigid thoracoscope through the trocar.

may be coughed out. In the absence of pleural effusion, the valve is not needed, but without it there is no protection against cough.

- The thoracoscope (Fig. 11.25) is advanced into the pleural cavity under direct vision through the trocar (Fig. 11.24).
- The pleural space can be inspected through the thoracoscope/pleuroscope, either directly (Fig. 11.25) or indirectly by video (Fig. 11.26).
- The pleural fluid is removed with a suction catheter placed through the working channel (or with a larger catheter directly introduced through the cannula).
- The thoracoscope is advanced toward the back and directed toward the diaphragm and the costophrenic angle.
- After completely removing the fluid, a systematic exploration of the chest cavity is performed by maneuvering the thoracoscope. In difficult cases, oblique telescopes are valuable to ensure adequate pleural inspection.

- The orientation is simple, although fine adhesions resembling spiders' webs may interfere with complete examination of the pleural cavity. These can be mechanically separated.
- However, fibrous bands or vascular adhesions should be avoided and can, if necessary, be cauterized by electrocautery.
- Optional: Air can be cautiously introduced to further collapse the lung and improve the inspection of the pleural cavity, but extreme care must be taken to avoid iatrogenic tension pneumothorax and subcutaneous emphysema when insufflating air into the pleural cavity.

The techniques used for sympathectomy and for pericardial fenestration are described separately in the sections of Chapter 3, pp. 48 ff. and 50.

Direct and Video-Controlled Inspection

The pleural space can be inspected through the thoracoscope, either directly or indirectly by video. Historically, direct-vision telescopes were used (Figs. 11.13 and 11.25). Today, most if not all centers use video assistance (Figs. 11.1 and 11.26). This allows for a technically easier and safer (sterility!) procedure, allows others in the room to follow the procedure (didactic purposes), and generally produces images of significantly superior quality. Since video equipment and processors are available in most modern pulmonology departments, direct visualization will become obsolete (the commercially available pleuroscope is already a videoscope).

After induction of a pneumothorax, a 7- or 9-mm trocar is inserted in the pleural cavity. The thorascopes are introduced through the trocar (see Fig. 11.24). To prevent the lenses from fogging up, immerse the tip of the rigid telescope in warm sterile saline or use a defogging agent.

Once the pleural cavity is entered, almost complete visualization of the pleural cavity and lung is possible, if

there are no pleural adhesions present. The 0° optics are best for the initial overview. Most thoracoscopists will use the 0° telescope for the initial overview. It allows inspection of most of the pleural cavity using a "natural," circular movement. Oblique angle telescopes may be used for a more panoramic, "periscope-like" viewing of the pleural cavity, if needed. Visual exploration can be performed in a few minutes. The entire pleural surface should be inspected in a systematic fashion including the parietal pleura of the chest wall, diaphragm, lung, mediastinum, heart, and vascular structures.

Anatomical relationships and intrathoracic structures are usually well recognized:

- The orientation on the right can be achieved by locating the point where the three lobes meet, the junction of the oblique fissure and horizontal fissure.
- On the left, the oblique fissure can be used for orientation.
- The diaphragm can be recognized because of the respiration-related movement.
- Ribs, intercostal muscles, fat, blood vessels, and nerves are usually well distinguished.
- The positions of the large vessels such as on the left the aorta and subclavian, and on the right the vena cava and the innominate vein as well as the subclavian artery, are readily recognized (Figs. 10.1 and 10.2).
- The heart and the great vessels are identified due to the pulsation, occasionally transmitted to adjacent parts of the lung.

In case of a large pleural effusion, the fluid should be aspirated completely and not too hastily; without risk of development of immediate reexpansion edema, as long as air is allowed to enter the pleural space to replace the aspirated volume (equal pressure procedure).

A probe or the optical forceps enables the physician to push aside any fibrinous strands interfering with clear view. If necessary, firm adhesions should be divided by electrocautery. In some situations, pleuroscopy with the

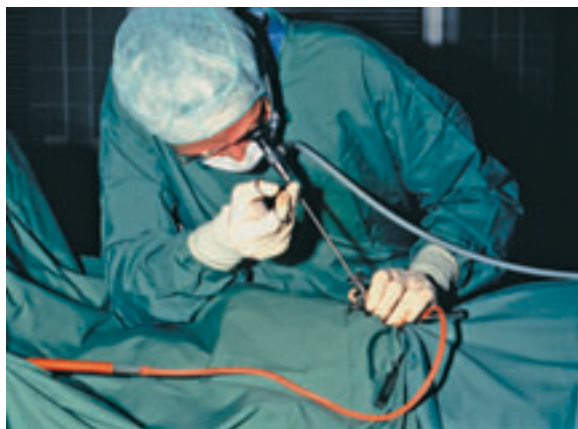

Fig. 11.25 Direct inspection through the rigid thoracoscope (while taking a biopsy).

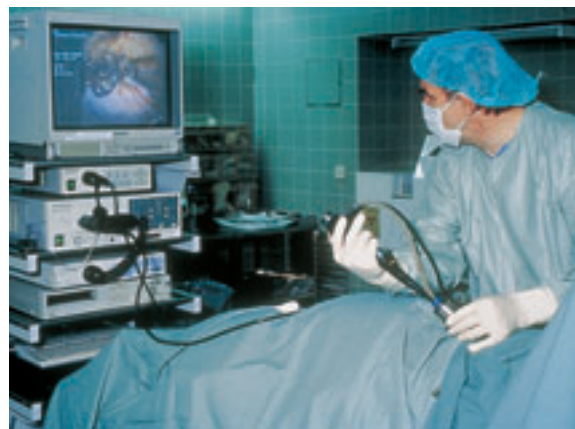

Fig. 11.26 Indirect, video-controlled inspection of the pleural cavity through the semiflexible pleuroscope.

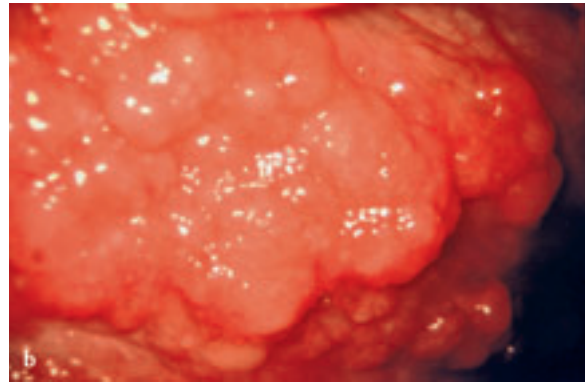
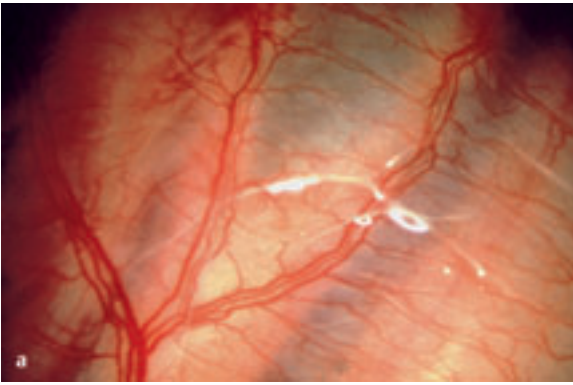


Fig. 11.27 **a** In its normal state, the pleura is transparent, allowing the visualization of ribs, fat, and vessels through it. **b** Extensive “mushroom” lesions, typical of malignant pleural invasion.

flexible tip may allow one to look into the area behind the adhesions.

In its normal state the pleura is transparent, allowing visualization of many structures through it. Variable amounts of anthracotic pigment can occasionally be seen within the parietal pleura. Fatty collections are often abundant in the pleura. These are long, yellowish plaques located along the ribs and around the pericardium and diaphragm. Extensive pleural disease is easily recognized, but localized disease or small, isolated nodules may be overlooked.

One of the hardest tasks for the endoscopist is to distinguish between innocuous inflammation and malignancy. It is almost impossible to tell the difference merely by visual observation. Certain patterns of pleural lesions can be seen: lymphangitis appears as a fine reticular pattern, covering part of the pleura; granulomata are 1–3 mm in diameter, seen with tuberculosis or sarcoidosis; and malignant nodules are variable in size and shape (fluorescent light [Chrysanthis and Janssen 2005] or narrow-band imaging [Schönfeld et al. 2009; Ishida et al. 2009; Froudarakis and Noppen 2009] might improve the identification of suspicious areas).

The lung looks like a cone, narrowing at the apex. Variable adhesions between the visceral and parietal pleura may be seen. When the lung is normal, the surface is pink and soft, with a reticular pattern demarcating the pulmonary lobules, and black anthracotic pigment is scattered over the surface. The visceral pleural surface is transparent. Areas of atelectasis are purplish red with a clear edge. Malignant nodules and other typical pathologies are quite easily seen, as are emphysematous blebs/bullae protruding from the surface (see *Atlas* section).

The observation should be performed from a distance to obtain a panoramic view and then from distance of 1–2 cm for inspection of the cavity very carefully to select the best biopsy sites. Suspicious areas are biopsied through the working channel of the thoracoscope using ei-

ther a 3- or 5-mm biopsy forceps (see “Biopsy Techniques” below). All abnormalities are systematically recorded.

Biopsy Techniques

Biopsies of the parietal pleura will be performed in most MT/Ps performed for the diagnosis of unexplained pleural effusions. In its normal state, the pleura is transparent, allowing the visualization of ribs, fat, and vessels through it (**Fig. 11.27a**). Chronic pleural inflammation may lead to a thickened, nontransparent pleura. Malignant lesions often have a characteristic “mushroom” appearance (**Fig. 11.27b**), but it may be impossible to differentiate thickened pleura from malignant invasion, e.g., in case of mesothelioma (**Fig. 15.9** in the *Atlas* section). Multiple biopsies are therefore often necessary. If lesions are present on the parietal pleura, rather than visceral pleural lesions, these should be biopsied, thus avoiding the risk for prolonged air leak.

Before pleural biopsy, the rib and intercostal space should be identified with a blunt probe. If the pleura is thick, the rib will feel hard compared with the spongy intercostal space. If possible, biopsies should always be taken against a rib, minimizing the risk of vessel or nerve injury. However, when the pleura is thick, taking the biopsy is simple with minimal risk of injuring the intercostal arteries. By contrast, when the pleura is thin, the biopsy should certainly be performed against one of the ribs.

Parietal pleural biopsies can be taken with the single-port single-instrument rigid technique, using an optical biopsy forceps with an attached 4-mm telescope (**Fig. 11.28**) or through the pleuroscope (**Fig. 11.29**). Using an optical biopsy forceps, the parietal pleura is grasped and gently pulled toward the operator. It is then pulled sideways, and in a shearing motion a “strip” of pleura can be isolated. Sometimes, large specimens several centimeters long can be obtained in this way.

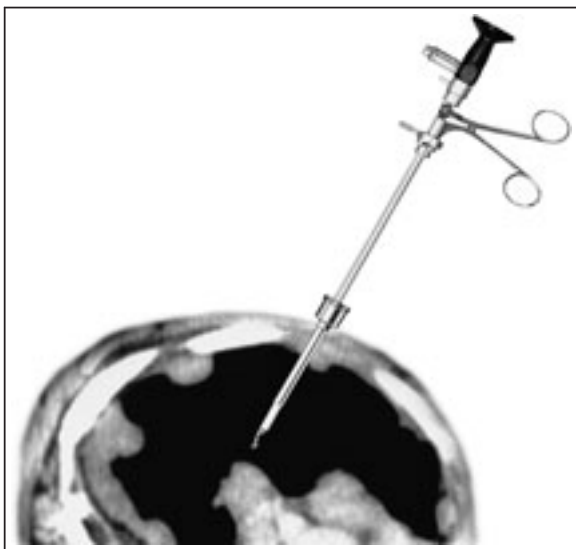


Fig. 11.28 Diagram superimposed on a CT image showing several malignant lesions of the parietal pleura from which biopsies can be taken under visual control through the thoracoscope.

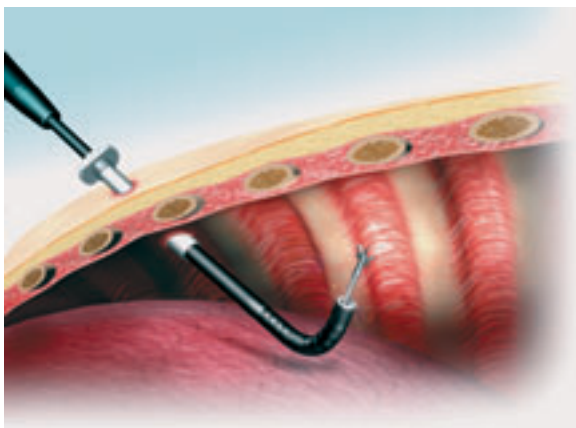


Fig. 11.29 Drawing showing the semiflexible pleuroscope introduced through the trocar shaft into the pleural cavity. The flexible forceps is introduced through the pleuroscope and directed toward the parietal pleura for taking a biopsy. (Reprinted with kind permission from Olympus Corporation.)

Typically two to six biopsies of a suspicious pleural lesion will establish a diagnosis. Sufficient quantities of tissue must be obtained, especially if hormonal receptor studies are required for tumors such as carcinoma of the breast. In the presence of undiagnosed pleural effusions, biopsies should be taken at a minimum from macroscopically suspicious lesions at the anterior and posterior chest wall and the diaphragm for histological evaluation, and, if suspicious for tuberculosis, also for mycobacterial culture.

When malignancy is suspected but the endoscopic findings are nonspecific, the total number of biopsies should be increased to up to 10–12 from a variety of areas

on the pleural surface (in the future, autofluorescence as well as narrow-band imaging might be helpful in identifying suspicious areas). Attention should be paid to fibrinous tissue/nodules that may mask malignant pleural lesions. These should be removed with the forceps, and the biopsy taken from the base of the lesion. Biopsies of suspicious lesions and of parietal pleura may cause some oozing of blood, which usually can be controlled by applying local pressure with the tip of the forceps, with epinephrine-soaked gauze, or by coagulation using an electrocautery forceps.

The principal danger for a beginner thoracoscopist/pleuroscopist is hemorrhage from the inadvertent biopsy of an intercostal vessel. This is an extremely rare event when using rigid instruments, and it is even less likely with smaller flexible forceps. If bleeding occurs, immediate external finger pressure should be applied to the intercostal space while preparation is made either for local pressure with epinephrine-soaked gauze or for cauterization of bleeding vessels and tissues with the coagulating forceps or probe.

Contraindications for pulmonary biopsy are suspicion of arteriovenous pulmonary aneurysm, vascular tumors, and hydatid cysts. Taking biopsy samples of honeycomb lung from end-stage pulmonary fibrosis should also be avoided as it contributes to high incidence of broncho-pleural fistulae.

To aspirate cysts, we use the operating bayonet optics attached to an adequately calibrated needle and stylet. Cysts are evacuated by means of a suction pump. Evacuation of pericardial cysts is undertaken using a syringe, with which one must proceed with a very steady hand and avoid certain movements.

Biopsies from the lung can be taken without difficulties with the single-port technique. Hemorrhage can be controlled by means of electrocautery, although in practice, this is rarely necessary since only minimal bleeding occurs from the small peripheral vessels, especially if the biopsies are taken from the edge of the lung lobes. The advantage is that the lung shrinks around the biopsy hole, ensuring both hemostasis and aerostasis.

However, some thoracoscopists prefer the two-port technique for lung biopsy. One (or two) additional points of entry can be made under direct thoracoscopic guidance as needed (**Fig. 11.30**). This may be the case when extensive adhesions are present (see **Fig. 11.14** and **Figs. 19.5** and **19.6** in the *Atlas* section), when the single entry site does not allow for complete inspection or does not allow one to reach a suspect lesion for biopsy, when more elaborate procedures are indicated (e.g., extensive adhesiolysis, visceral pleura/lung biopsies, sympathectomy) (Lee and Colt 2003 b), or when it is necessary to control hemorrhage after biopsy. The position of the second point of entry is determined by viewing through the oblique scope while depressing the possible entry site with the index finger. It is sometimes helpful to insert a needle through the same site while viewing its precise location through

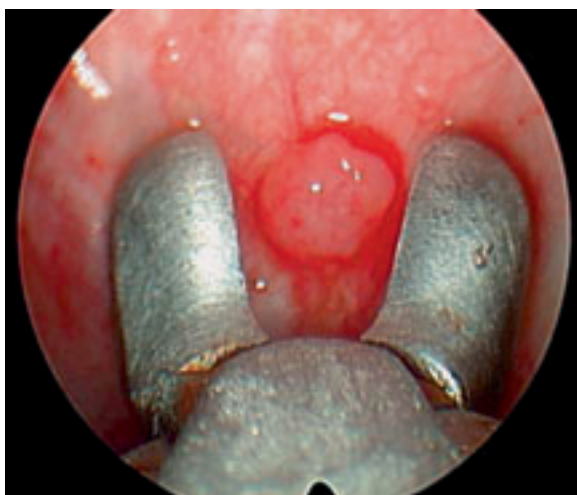


Fig. 11.30 Parietal pleural biopsy using a two-port technique. The cups of the 5-mm forceps are opened on top of a rib; the pleura is grasped and gently pulled sideways.

the thoracoscope. After administering a local anesthetic, a 5-mm incision is made and the 5-mm trocar is inserted directly.

When MT/P is performed under general anesthesia, the two-port technique is most often used. The accessory instrumentation is usually passed through a 5- or 7-mm insulated trocar. Its cannula will accommodate many instruments designed for its smaller bore. The principles of biopsy of the parietal pleura are the same as described above. Usually, a 5-mm double-spoon insulated coagulation forceps is used. This two-port thoracoscopy may be preferred when pleural metastases are located on the visceral pleura (usually with similar “mushroom” appearance), when isolated or multiple lung parenchymal nodules are present (usually identifiable by umbilication of the visceral surface, or by gentle palpation), or in case of diffuse interstitial lung disease.

The coagulation forceps is positioned perpendicular to the lung; the lung is grasped, the forceps is closed and pulled toward the 5-mm trocar. As the forceps is pulled into the trocar, electrocautery (set at 60–100 W) is applied, with a foot pedal, for about three seconds. The pulling through the sharp end of the trocar “guillotines” the lung, and the electric current provides coagulation and closure of the lung surface. Leaks, when present, are usually small and close spontaneously. Bleeding is rare, as long as the fissures are avoided. Also, biopsies should be avoided in case of bullous lung disease and in case of end-stage lung fibrosis. In cases where diffuse infiltrates are evident on a CT scan, samples should be taken from healthy as well as abnormal areas. An average of 3–4 (range 1–8) biopsy specimens are obtained during any given session. The histological features of biopsy specimens are preserved sufficiently with this technique (Lee and Colt 2003a).

Boutin’s group has described the use of a YAG laser after lung biopsy to ensure airtightness. After removing samples of pulmonary parenchyma, the laser fiber is introduced and the pulmonary orifice is closed with 3 to 5 pulses (Boutin 1989; Boutin et al. 1991). The laser was also successfully applied for lysis of adhesions, for cauterization of emphysematous bullae in spontaneous pneumothorax, for coagulation of traumatic bleeding, and for the closure of pleuropulmonary fistulae.

Stapled Wedge Resection

Lung biopsies can alternatively be performed by experienced thoracoscopists using 3-cm reloads and an endoscopic stapler. Endoscopic staplers cut and staple lung parenchyma, preventing air leaks and bleeding. Stapling makes it easier to obtain vessels and also results in less air leakage. The procedure is usually performed in an operating theater, with the patient under general anesthesia and selectively intubated. Nezu and colleagues describe a technique that allows wedge resection of blebs with the patient under local anesthesia (Nezu et al. 1997). The patient is premedicated with meperidine, 50 mg, and atropine sulfate, 0.5 mg, given intramuscularly. Thirty minutes before surgery, 0.5% lidocaine is instilled into the pleural cavity and 5 mg of diazepam is administered intravenously for pain and anxiety. Thoracoscopic wedge resection of the pulmonary parenchyma at the base of the bleb is performed through two 5-mm ports, which accommodate a rigid telescope and grasping forceps and a 12-mm port for the stapler. This is followed by pleural drainage with a 24 F chest tube. Nezu’s procedure was successful in all but two patients, and morbidity was minimal. Aside from minor discomfort at the portal sites, local anesthesia and sedation were adequate in all cases.

Caution: Biopsies in perihilar areas must be performed with extra care because of the presence of the pulmonary vessels crossing through the lobes. Fissures themselves, particularly in a peripheral aspect, pose no more danger than working on a flat surface of the lung periphery. Similarly, it is prudent to avoid biopsy of an emphysematous bulla, cyst, or cavity because of significant potential for a prolonged air leak from a bronchopleural fistula. In a patient with honeycomb lungs, any necessary random biopsy specimens should be taken from the mid and upper lung, where emphysematous bullae and cysts are relatively sparse. The average dry weight of lung biopsy specimens ranges from 4 to 37 mg. Cup forceps biopsy is probably best avoided in these patients. When using a stapler device, special care is necessary to avoid tearing the fragile lung parenchyma with either the stapler or the grasping forceps.

If malignant disease is obvious, and if all fluid has been removed, the biopsy procedure can be followed immediately by insufflation of talc for pleurodesis.

Performance of Semirigid (Semiflexible) Pleuroscopy

The principles of trocar introduction and pleural cavity inspection are similar to those for the rigid instrument. **Figure 11.1** shows it being performed. The semirigid pleuroscope has the “look and feel” of a flexible bronchoscope, and thus may “lower the threshold” for thoracoscopy for the pulmonologist, and may even become more popular than the classical rigid instrumentation.

The semirigid pleuroscope (model LTF 160, Olympus, Japan) has been described in detail earlier. The design, including the handle, is similar to that of a standard flexible bronchoscope and thus the skills involved in operating the instrument are already familiar to the practicing bronchoscopist. Furthermore, it is compatible with the existing video-processors and light sources. The optical quality allows excellent visual exploration as well as good video or photographic documentation. The flexible tip will allow various angles of vision, including straight-ahead and oblique angle of view (see **Fig. 11.6b** and **11.29**). As with a bronchoscope, one very quickly becomes accustomed to the movement of the tip by simply rotating the pleuroscope and manipulating the tip to afford a superb panoramic view of the entire pleural cavity.

Otherwise, the step-by-step performance is similar to the already described technique of rigid medical thoracoscopy via a single entry.

Comparison of the Rigid and Semirigid Techniques

Advantages of the Rigid Thoracoscopic Instruments

- Specimens obtained with the rigid forceps are significantly larger than those with the semirigid pleuroscope as they are limited by the size of the flexible forceps (**Fig. 11.31a–c**), which in turn depends on the diameter of the working channel (McLean et al. 1998; Lee and Colt 2005; Lee et al. 2007a). However, this technical limitation can be overcome by taking multiple biopsies of the abnormal areas as well as several “samples” of the same area to obtain tissue of sufficient depth (Lee and Colt 2005; Lee et al. 2007a).
- Besides larger biopsy sizes, the rigid forceps allows taking of biopsies from very dense lesions as well (although the coagulation forceps, or a diathermic knife [Kawahara et al. 2008], used with the semirigid pleuroscope may solve this problem in part).
- The rigid instruments are more suitable when more elaborate procedures are indicated (e.g., extensive adhesiolysis, visceral pleural/lung biopsies, sympathicolysis), or when it is necessary to control hemorrhage after biopsy.

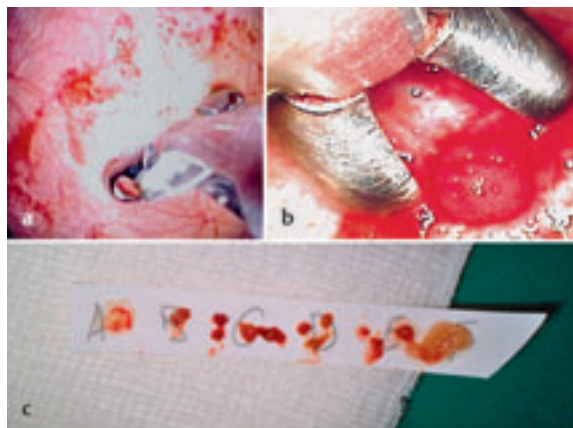


Fig. 11.31 Comparison of biopsies obtained with a flexible biopsy of the parietal pleural (a) and rigid optical forceps (b). c Specimens taken with the flexible forceps (A–E) are smaller.

- Rigid instruments are less expensive, more robust, have a longer endurance and may need maintenance and repair less often.

Advantages of the Semirigid Pleuroscope

- The semirigid thoracoscope has the “look and feel” of a flexible bronchoscope, and thus may “lower the threshold” for medical thoracoscopy for the pulmonologist. It may also be helpful psychologically in overcoming fear of using the rigid (and therefore often regarded as more dangerous) instruments.
- It interfaces easily with existing processors (CV-160, CLV-U40,) and light sources (CV-240, EVIS-100 or 140, EVIS EXERA-145 or 160) made by the manufacturer for flexible bronchoscopy or GI endoscopy, which are available in most endoscopy units without additional cost.
- It helps maintain a clear optical field by allowing concurrent suctioning, which is analogous to the suction techniques used during flexible bronchoscopy.
- It may allow one to overcome a limited view by maneuvering its flexible tip in different directions and around adhesions (Lee and Colt 2005; Lee et al. 2007a).
- Its flexible tip facilitates the homogeneous insufflation of talc (via a catheter, introduced through the working channel) into all areas of the parietal and visceral pleura (see **Fig. 11.11a**).

The ideal is certainly the combination of both techniques, in which rigid medical thoracoscopy can be complemented by the semiflexible pleuroscope in the above-mentioned advantageous situations, which is comparable to the combined use of rigid and flexible bronchoscopy in complex therapeutic endobronchial indications.