

## Chapter 1

### The Deltoid Fasciocutaneous Flap

The deltoid free flap is a neurovascular fasciocutaneous tissue, providing relatively thin sensitive tissue for use in soft-tissue reconstruction. The deltoid fasciocutaneous flap was first described anatomically and applied clinically by Franklin.<sup>1</sup> Since then, the deltoid flap has been widely studied and applied.<sup>2-5</sup> This flap is supplied by a perforating branch of the posterior circumflex humeral artery and receives sensation by means of the lateral brachial cutaneous nerve and an inferior branch of the axillary nerve. This anatomy is a constant feature, thus making the flap reliable. The ideal free deltoid flap will be thin, hairless, of an adequate size, and capable of sensory reinnervation. These characteristics of the flap make it an attractive option for reconstructing defects of the orofacial region. However, in adipose individuals, the fat tissue might add to the bulk of the flap.

#### Preparation

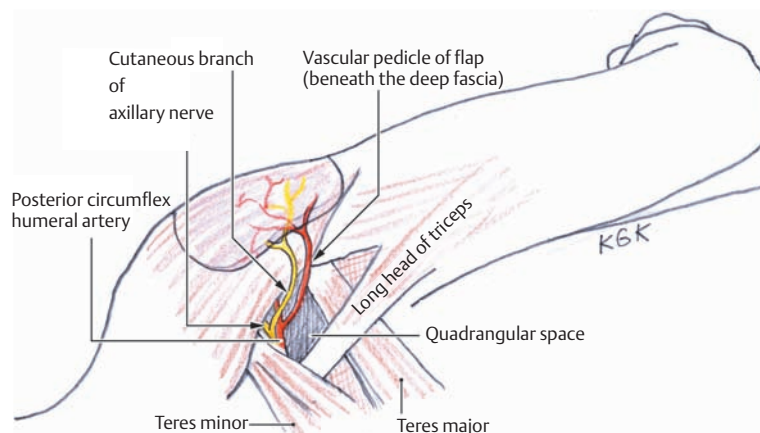
The course of the neurovascular pedicle is determined and marked before surgery as follows. With the patient in sitting or standing position, the acromion and the lateral humeral epicon-

dyle are palpated and marked. A straight line is marked to connect these two landmarks. The groove between the posterior border of the deltoid muscle and the long head of triceps is palpated and marked. The intersection of these two lines denotes approximately the location of the vascular pedicle, as it emerges from underneath the deltoid muscle. This point may be studied with a hand-held Doppler and marked if required.

Depending on the recipient area, the patient is positioned either supine, with the donor shoulder sufficiently padded with a stack of towels, or in the lateral decubitus position. Myo-relaxants are required in muscular individuals, so as to ease retraction of the posterior border of the deltoid muscle, especially if a long vascular pedicle is required for reconstruction.

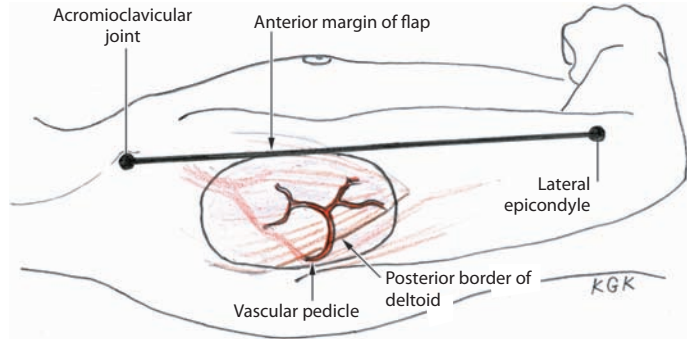
#### Neurovascular Anatomy

A large portion of the fasciocutaneous territory overlying the deltoid muscle is nourished by the posterior circumflex humeral artery with its paired venae comitantes (Fig. 1.1). The sensory innervation of this skin area is through the lateral brachial cutaneous nerve, which is the terminal sensory branch of the axillary nerve, a musculocutaneous nerve arising from the posterior cord. This nerve accompanies the vascular pedicle, passing behind the humerus and emerging from the quadrangular space, which is bordered by the teres major muscle below,



**Fig. 1.1** Anatomical basis of the deltoid flap.

**Fig. 1.2** Planning markings of the deltoid flap.



teres minor muscle above, long head of triceps medially, and the lateral head of triceps laterally. The vascular pedicle gives off branches to the deltoid muscles before its emergence. The nerve, as already mentioned, is a musculocutaneous nerve and provides motor innervation to the deltoid muscle. The neurovascular pedicle emerges at the posteroinferior border of the deltoid muscle, turns cranially after its emergence, and supplies the skin overlying the posterolateral aspect of the deltoid muscle. Thus a safe flap will be carved behind the line connecting the acromioclavicular joint and the lateral epicondyle, with an adducted and internally rotated arm (Fig. 1.2).

### Incisions and Dissection

With the patient's arm adducted and internally rotated, three lines are drawn<sup>1</sup>: a line connecting the acromion and the lateral epicondyle,<sup>2</sup> a line along the groove between the posterior border of the deltoid muscle and the long head of triceps, and a line connecting the acromioclavicular

junction with lateral epicondyle.<sup>3</sup> The intersection of the first two lines denotes the point where the vascular pedicle emerges to the surface behind the deltoid muscle; whereas the third line should ideally be the anterior border of the planned skin flap. Any variation in the point of emergence of the vascular pedicle can be marked before surgery using a handheld Doppler.

The anterior border of the marked skin flap is incised first, extending it along the inferior border as required. The deep fascia overlying the deltoid muscle is sharply cut and the flap is elevated in a plane underneath the fascia. Dissection proceeds toward the vascular pedicle, which is visualized in the under surface of the flap, after partially raising it (Fig. 1.3). An occasional perforator from the deltoid muscle should be coagulated and divided. The neurovascular pedicle is traced to the delto-tricipital groove and carefully isolated. Now the rest of the skin incision can be completed (Fig. 1.4). The posterior border of the deltoid muscle is retracted to gain length of the vascu-

**Fig. 1.3** Dissection of the deltoid flap.

