

## 2

# Advanced Image-Guided External Beam Radiotherapy

Thomas Rockwell Mackie and Wolfgang Tomé

## Introduction

In 2003, Schultz and Kagan speculated that even with a perfect ability to deliver the ideal radiation dose distribution, it would be unlikely that outcomes would be improved. They imagined a perfect radiation treatment machine, which they called the “Infinatron,” that could deliver a dose distribution with any dose level and a zero dose outside of the target volume. They proposed that the Infinatron might not be preferable to surgery except for the reduced morbidity that would accompany its use. Schultz and Kagan were overly pessimistic as their argument that better radiation technology would not affect cure was easily countered by Keall and Williamson (2003) who provided several examples to the contrary. However, Schultz and Kagan (2003) were correct on one point; without the knowledge of where the disease is and where it is not present, the Infinatron could not guarantee a cure. As more and better treatment systems to deliver radiation come into existence, the key to their use will be to identify the target volume more exactly and to ensure that the targeted region is treated as prescribed.

Radiation therapy treatment planning was the first application to use quantitative imaging in medicine to determine an accurate representation of the patient including the tumor volume. Other allied fields such as radiology and surgery traditionally used images in a qualitative sense. Images have long been used to determine the position and extent of the tumor. In modern radiation therapy, CT images are routinely used to obtain density and tissue type information in order to determine tissue attenuation accurately. More recently, images are used not just to determine physical quantities but are also increasingly being used to incorporate biological information into the treatment planning process [1–4].

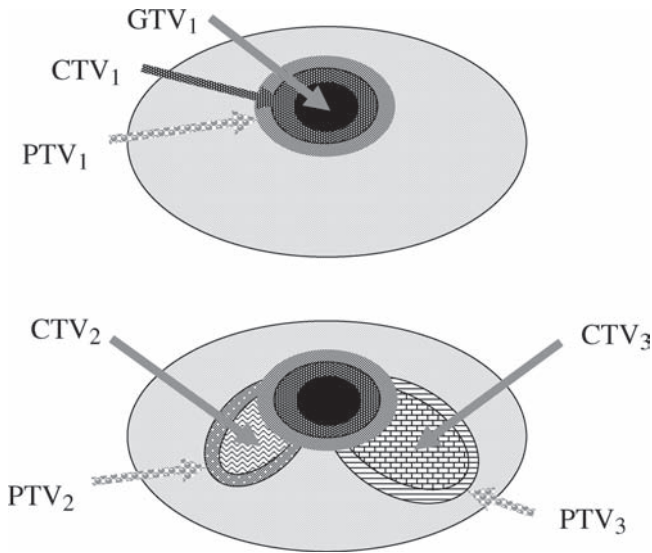
The goal of radiation therapy research and development is to increase the chance of tumor control and/or reduce the chance of causing harm to normal tissues. 3D imaging modalities can pinpoint the location of many anatomical structures within the body, and their function can be mapped with reasonable precision. Intensity-modulated radiotherapy (IMRT) can deliver radiation to target volumes of complex shape (ASTRO/AAPM 2001) [5–8] and so it is now possible to improve the delivery of radiation to those regions that are truly afflicted and to avoid better those areas that

are at risk of radiation injury. With IMRT, it is possible to increase the magnitude of the gradient between the target and normal tissue, which places more demand on imaging as a verification tool for this form of radiation delivery.

Until the advent of 3D imaging systems, the extent of the diseased volume was uncertain unless surgery was performed. This is because the exclusive use of 2D images presupposes an underlying shape in order to deduce volumes. For example, the tradition of staging tumor size based on lineal measurements in orthogonal planes is from an earlier era when 2D imaging was dominant. 3D CRT planning systems can augment the poor image quality of planar radiographs and improve their comparability with CT by the construction of digital reconstructed radiographs (DRRs) from CT [9, 10] or even MR [11] image sets in the same treatment setup and beam position as the radiographs. However, when mismatches occur between DRRs and planar radiographs, the reasons are usually not readily obvious or easily determined. Radio-opaque markers can be placed in certain structures such as the prostate to assist in its localization with EPIDs [12–14] but this is a highly invasive procedure and does not have universal applicability.

The International Committee of Radiation Units and Measurements (ICRU) have developed nomenclature and procedures for defining tumor and normal tissue structures in radiotherapy [15, 16]. 3D imaging modalities such as computed tomography (CT), magnetic resonance imaging (MRI), and positron emission tomography (PET) have enabled ever more precise localization of the gross tumor volume (GTV) for many sites and most sensitive structures. The location of microscopic extensions of the tumor around the GTV remains uncertain because tumor extension or tumorlets visible close to the GTV have to consist of millions of cells to be visible on a PET scan, typically the most sensitive (not necessarily the most specific) imaging system for cancer. The concept of clinical target volume (CTV) surrounding the GTV with a margin for invasion undetectable by current imaging systems is used to define the region of presumed spread that is inferred occasionally by evidence from pathology but usually only by clinical experience [15, 16]. A margin around the CTV defining a volume called the planning target volume (PTV) takes into account uncertainties affecting the precise treatment of the target volume. The uncertainty arises because the target volumes cannot be set up precisely from day to day, the organ shape and position may vary due to organ filling (or voiding), the patient may have lost (or gained) weight, the tumor may have shrunk (or grown), or the organ could be in periodic motion. In modern radiotherapy, the dose given to the GTV is typically higher than the dose applied to the CTV. If the dose difference is substantial, a PTV margin should also surround the GTV to ensure that it is getting adequate dose. Figure 1 illustrates the concepts of GTV, CTV, and PTV [15, 16].

In-room image guidance is also not a new topic. 2D image guidance using portal imaging systems has been used for decades. The current state of the art for curative radiotherapy is to produce a portal image once a week, which is an image of the beam exiting the patient [17–19]. This may be acquired with radiographic film but increasingly electronic portal imaging detector (EPID) systems are used. EPIDs are an improvement over film because they are less sensitive to over- or underexposure and there is an opportunity for image enhancement [20–23]. EPIDs have been used to automatically correct patient setup, for example, using a “tilt and roll” couch



**Fig. 1** Illustration of the use of the concepts of gross tumor volume (GTV), clinical target volume (CTV), and planning target volume (PTV). In the *upper figure*, a CTV ( $CTV_1$ ) is the margin for microscopic tumor extension surrounding  $GTV_1$ . The dose prescription is assigned to the PTV ( $PTV_1$ ) which is the extension to account for setup variation and organ motion. In the *lower figure*, in addition to  $CTV_1$ , there are clinical target volumes ( $CTV_2$  and  $CTV_3$ ) that are the regional extensions of the disease. Correspondingly, the planning target volumes account for setup variability and organ motion. The dose prescriptions for  $PTV_1$ ,  $PTV_2$ , and  $PTV_3$  could be all different

[24]. Many investigators have shown that it is possible to collect the “exit dose” from the EPID signal [25–30]. This exit dosimetry information could be compared to the exit dose calculated from the treatment plan and employed as the basis to halt the treatment.

Even the best portal images will be inferior to typical diagnostic X-ray planar radiographs because of the smaller focal spot size in X-ray tubes and higher bony contrast of diagnostic X-rays. Planar radiographs are difficult to interpret because they are not in reference to 3D CT image sets and out-of-plane rotations of the patient are not as readily evident as translations [31–33].

### ***Image Guidance for Defining Target Volumes***

Of all likely uncertainties in radiotherapy, position and extent of the contoured volumes have the greatest uncertainty. The CTV margin is almost never satisfied by a simple constant distance extension around the GTV. Many studies have shown that the accuracy of the definition of the CTV is not accurate to even 10s of percent in the lung [34–36], esophagus [37], breast [38], bladder [39, 40], and cervix [41].

A major goal of future radiotherapy procedures and systems will be to reduce the uncertainty in tumor extent and location as well as to reduce the uncertainties related to treatment delivery. The conventional fractionation paradigm of radiation therapy has been predicated on relatively large treatment volumes, which irradiate a large volume of normal tissue. The conventional 2Gy per fraction has been established during the era of 2D treatment planning. As target volumes are reduced due to improved imaging, fractionation schedules should be re-evaluated. Recent evidence indicates that many target volume sites are likely to respond to higher doses per fraction [42] without impacting normal tissue tolerance. The  $\alpha/\beta$  ratio for prostate carcinoma is likely to be low [43–48] as compared to other treatment sites, with estimates as low as 1.5 instead of the 8–10 typical for early responding tissues and tumors. In lung cancer, there is evidence that the dose per fraction should be increased and the overall time should be shortened [49, 50] to avoid wasted dose because of accelerated repopulation of the tumor. IMRT is enabling a higher dose per fraction to be more safely delivered because the dose per fraction to normal tissues is not significantly increased [51]. This will increase the importance of image guidance because a higher dose per fraction will decrease the number of fractions treated; hence the increased effort of image guidance is justifiable. All of these strategies taken together will reduce the margins around the GTV and reduce the amount of integral dose that needs to be deposited in the patient.

There are two types of CTV. The first type takes into account that an occult microscopic disease exists around the visible tumor extent defined to be the GTV. If there are no highly sensitive normal tissue structures close to the GTV, a CTV accounting for the microscopic extension typically receives a dose close to or equal to that received by the GTV. This use of CTV is illustrated in the upper panel of Fig. 1.

Reducing the uncertainty of the microscopic extension of the tumor is a difficult task. The CTV margin for some sites like breast might be too generous (hence the interest in partial breast radiotherapy) whereas for other sites like glioblastoma multiforme it might encompass most of the brain. What is needed is a three-pronged research attack on the problem:

1. High-sensitivity and potentially high-specificity imaging systems, such as PET, correlated with image-registered pathological specimens should be used to help delineate disease extent from normal tissue at the tumor periphery so that knowledge of the probability of spread can be determined. This approach attempts to make occult disease visible, in effect, turning CTVs into GTVs.
2. Outcome analysis has to be precisely quantified so that it can be determined whether or not patients are failing at the margin or within the tumor. This will be a tremendous complement to dose escalation trials because even extremely high doses will not be sufficient to eradicate high probability tumors that are routinely missed [52].
3. Begin treating patients with a conformal avoidance methodology in addition to conformal radiotherapy; this allows for the use of modestly large CTV margins while still sparing critical normal structures.

Radiation therapy treatment planning requires sufficient sensitivity and specificity to be able to delineate tumor and normal tissues with confidence. CT, alone or fused with other imaging modalities [53], is still the predominant imaging modality on which the delineation of most tissue structures is based. Improved CT contrast agents have led to improved definition of tumor boundaries. CT simulation with 3D treatment planning is now conventional practice in all radiotherapy centers and the need for conventional simulators in radiotherapy departments has been called into question [54]. Even with dedicated 3D imaging systems common in the clinic and a generation of radiation oncologists trained in their use, there is considerable variation of the GTV for many sites [55].

MRI is gaining in importance in radiation therapy. Usually, the MRI scans are fused with CT scans and the MRI is used to aid in delineation of tumor volumes and normal structures. Dedicated MRI simulation that eliminates the need for fusion is being investigated for sites, like prostate, for which tissue heterogeneity dose calculation algorithms are not necessary [56]. MRI is now the preferred way by which most central nervous system malignancies are delineated [57, 58]. Even though its resolution is not comparable with conventional MR images, magnetic resonance spectroscopy (MRS) is being used to determine the location of the most active disease site within the prostate, in effect, identifying the GTV within the prostate CTV volume [59–62]. Selective boosting of active disease will require excellent tumor and target localization at the time of treatment [cf. 52].

The best MRI or contrast CT imaging today is capable of defining tumors with a clonogen density of about  $10^6$  or  $10^7$  tumor cells per square centimeter as compared to  $10^9$  cells/cm<sup>3</sup> (range from  $10^8$  to  $10^{10}$  cells/cm<sup>3</sup>) for normal tissue. Tumorlets which have fewer than  $10^6$  cells extending over a cubic centimeter will not be visible.

The role of PET will be greatly enhanced by the new generation of PET/CT scanners from which fully correlated PET and CT images emerge. PET/CT simulators will augment or even replace CT simulators during this decade. Using PET images, one will be able to delineate the extent of the GTV and the CTV with much more precision. PET will begin to enable a probabilistic formulation for the GTV and CTV whereby the GTV is that region where the probability of the occupancy by tumor approaches 100% and the CTV is at the boundary where that probability approaches zero. The PET successors to Proscint scans might identify minimally involved lymph nodes in prostate cancer. Radiopharmaceuticals to complement <sup>18</sup>F<sub>2</sub>FDG, a good marker of proliferative metabolic activity in many cases, are emerging [63]. Labeling of proliferation, hypoxia, perfusion, even the status of the P53 gene in the tumor, will be possible [37, 64, 65].

The best PET imaging today is capable of improved sensitivity as compared to MRI or contrast-enhanced CT. That means that it may be possible to detect tumors with a density as low as  $10^5$  cells/cm<sup>3</sup>. This could be improved in a number of ways. The efficiency of tumor uptake could be improved. With faster PET detector electronics, the absolute activity of the isotope could be increased for patients undergoing radiotherapy. The scan times could be increased. Each of these factors would only increase the contrast by the square root of the counts detected and so