PREFACE

Gastrointestinal (GI) bleeding is an extremely common clinical problem resulting in more than 300,000 hospitalizations annually in the United States. The overall incidence of upper GI bleeding is approximately 125 hospitalizations for every 100,000 people, with a male to female ratio of 2/1. Lower GI bleeding is far less common. Interestingly, the mortality from upper GI bleeding has remained stable at 10% over the past 45 years, despite improved diagnosis and newer therapeutic modalities, although this may reflect, at least in part, the aging population with a significantly higher GI bleeding mortality. Fortunately, the mortality from lower GI bleeding has decreased dramatically, despite the higher risk among the aging population owing, in large part, to early detection and intervention. Although GI bleeding can be acute or chronic, mortality from acute GI bleeding is much greater than that for chronic bleeding. Therefore, it is important to understand the pathogenesis of acute GI bleeding, with an emphasis on early detection, prevention, and intervention, in order to minimize morbidity and mortality.

Acute Gastrointestinal Bleeding: Diagnosis and Treatment covers a wide range of topics, with particular emphasis on the pathophysiology, diagnosis, management, and treatment of various acute bleeding disorders. The general approaches to the acute GI bleeding patient are discussed in terms of supportive care, early detection and determination of upper vs lower GI bleed, when to transfuse, as well as early predictors of morbidity and mortality. Outlined in this volume are the many dilemmas faced by physicians in the approach to the acute GI bleeding patient, such as localization of the bleeding source (upper vs lower), the need and timing for emergent endoscopy, and the timing for radiologic intervention and/or surgery. The emphasis throughout is on patient management, diagnostic measures, and treatment modalities. Diagnostic and treatment algorithms for acute GI bleeding determined by evidence-based medicine and standard-of-care issues are included.

We hope that this book serves as a useful reference for both primary care physicians as well as gastroenterologists.

Karen E. Kim, *MD*

2 Nonvariceal Esophageal Bleeding

Christian Stevoff, MD
and Ikuo Hirano, MD

Contents

Introduction
Mallory-Weiss Lesions
Reflux Esophagitis
Esophageal Infections
Malignant Neoplasm
Miscellaneous Conditions
Conclusions
References

INTRODUCTION

The esophagus is an important site of acute upper gastrointestinal (GI) bleeding that typically presents with hematemesis or melena. A careful history is essential in assembling an accurate differential diagnosis. An antecedent history of vomiting, immunosuppression, medication use, and instrumentation in addition to symptoms of heartburn, dysphagia, and odynophagia is helpful in establishing a diagnosis.

The esophageal mucosa is normally devoid of large vessels that could cause rapid blood loss if damaged. In the absence of varices or bleeding diathesis, acute esophageal bleeding is caused by deep injury to the esophagus or abnormally superficial arterial branches. As it is common for many of the conditions discussed below to lead to shallow ulceration of the esophagus, it is more likely for esophageal bleeding to present

From: *Acute Gastrointestinal Bleeding: Diagnosis and Treatment*
Edited by: K. E. Kim © Humana Press Inc., Totowa, NJ

Table 1
Causes of Nonvariceal Esophageal Bleeding

- Mallory-Weiss tear
- Peptic esophagitis
- Infectious esophagitis
  - Viral
    - Herpes simplex
    - Cytomegalovirus
    - HIV
      - Primary
      - Bacillary angiomatosis
      - Nocardia
      - Actinomycoses
      - Mycobacterial
    - Epstein-Barr virus
    - Varicella zoster
    - Human papillomavirus
  - Bacterial
    - Tuberculosis
    - Syphilis
    - *Mycobacterium avium-intracellulare*
    - Actinomycosis
    - Other—*Staphylococcus aureus*, *Staphylococcus epidermis*, *Staphylococcus viridans* (hard to prove as primary cause)
  - Fungal
    - *Candida albicans*
    - Blastomycosis
- Caustic injury/pill esophagitis
- Neoplastic causes
  - Adenocarcinoma
  - Squamous cell carcinoma
  - Lymphoma
  - Stromal tumor
  - Metastatic disease—breast, melanoma, and other
  - Melanoma
  - Small cell carcinoma
  - Kaposi's sarcoma
  - Hemangioma
  - Squamous papilloma
  - Liposarcoma
- Cutaneous disorders
  - Epidermolysis bullosa
  - Pemphigus vulgaris

with a subacute or chronic course. However, given the high prevalence of conditions such as gastroesophageal reflux disease, the esophagus is a significant source of acute GI blood loss, accounting for approximately one-third of all acute upper GI bleeding cases.

Table 1 ***(continued)***

Cutaneous disorders
Bullous pemphigoid
Cicatracial pemphigoid
Tylosis
Erythema multiforme
Pseudoxanthem elasticum
Lichen planus
Stevens-Johnson syndrome
Inflammatory causes
Crohn's disease
Eosinophilic esophagitis
Sarcoidosis
Collagen vascular disease
Wegener's granulomatosis
Anti-cardiolipin antibody syndrome
Behçet's disease
Henoch-Schönlein purpura
Scleroderma
Amyloidosis
Ischemic esophagitis ("black esophagus")
Iatrogenic causes
Radiation
Chemotherapy
Graft-versus-host disease
Surgery
Photodynamic therapy
Endoscopy/transesophageal echocardiography for diagnosis or dilation
Sclerotherapy/banding
Vascular causes
Dieulafoy's lesion
Blue rubber bleb nevus syndrome
Arteriovascular malformation
Esophagoaortic fistula
Subclavian artery-esophageal fistula
Miscellaneous causes
Gastric inlet patch
Fibrovascular polyp
Esophageal intramural hematoma
Scurvy
Esophageal diverticulum
Foreign body

There are numerous causes of esophageal bleeding (Table 1). This chapter discusses specific etiologies with particular emphasis on the more common and clinically pertinent etiologies. Esophageal varices are the subject of another chapter in this book.

MALLORY-WEISS LESIONS

Mallory-Weiss lesions are tears occurring at or near the esophagogastric junction, secondary to mechanical stress most commonly induced by vomiting. Increased intraabdominal pressures during retching or vomiting combined with forceful propulsion of the gastric cardia through the diaphragmatic hiatus may cause enough force to lacerate the esophagogastric mucosa.

Mallory-Weiss lesions account for 4–14% of all cases of acute upper GI bleeding in patients who undergo endoscopy *(1,2)*. Most series report a male predominance of 60–80% *(3–6)*, with the mean age typically in the fourth to sixth decades *(3,6,7)*. Recent alcohol ingestion has been reported in 21–80% of cases *(5,8,9)*. Importantly, a history of antecedent vomiting or retching is only reported in 30–85% of patients *(1,2,6)*. Hematemesis is a presenting symptom in 85–95% of cases *(2,9)*. Any condition causing vomiting could produce a tear, including coughing, cardiopulmonary resuscitation, pregnancy, and even colonoscopy preparation *(10–14)*. A Mallory-Weiss tear secondary to endoscopy is uncommon and rarely leads to severe bleeding *(13,15)*.

The diagnosis of Mallory-Weiss lesions is best made endoscopically with close inspection of the gastroesophageal junction. Barium swallows have poor sensitivity and are not recommended. The lesion is longitudinal, most commonly along the posterior aspect of the lesser curve of the gastric cardia, extending proximally to include the distal esophagus (Fig. 1) *(6)*. In over 80% of cases, a single tear exists *(5,6)*, averaging 0.5–5 cm in length *(16)*. Although esophageal involvement is common, only rarely is the lesion confined to the esophagus alone *(6,17,18)*. The presence of hiatal hernia is associated with a more distal laceration, perhaps sparing the esophagus altogether *(18)*. This is probably caused by proximal displacement of the esophagogastric junction from the diaphragmatic hiatus. Such lesions need to be distinguished from Cameron's erosions, although the latter typically presents with chronic GI blood loss. Several series have reported up to a 75% prevalence of hiatal hernias in patients presenting with bleeding Mallory-Weiss lesions *(5,16,18)*; however, one large series reported only 17% *(6)*.

The bleeding associated with Mallory-Weiss lesions is usually self-limited, with spontaneous cessation of bleeding reported in 90% of cases *(6)*. Protracted bleeding can occur, however, and active bleeding has been noted endoscopically in 25–55% of patients *(6,9)*. In 20–50% of cases, hypotension < 100 mmHg and tachycardia > 100 bpm are presenting features *(9,16)*, and 30–75% require blood transfusion dur-

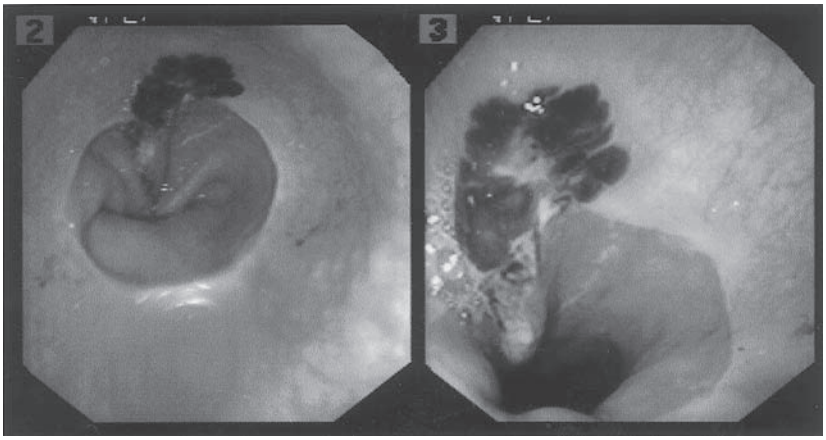

Fig. 1. Endoscopic view of a Mallory-Weiss tear straddling the squamocolumnar junction in the presence of a hiatal hernia

ing the hospital course *(5,6)*. A mortality of 0–13% has been reported in patients presenting with Mallory-Weiss lesions; however, not all the deaths were attributed to bleeding *(3,19–21)*. A recent series *(1)* attempted to define characteristics that would select a subset of patients with bleeding Mallory-Weiss lesions who exhibited a low likelihood of rebleeding, thereby not requiring admission to the hospital. The study noted that patients with portal hypertension or bleeding diathesis, including that caused by nonsteroidal antiinflammatory drugs (NSAID) use, were at increased risk of rebleeding. Patients with active bleeding at endoscopy were more likely to be treated endoscopically and received more blood transfusions.

Several endoscopic therapies have been described in the treatment of actively bleeding Mallory-Weiss lesions; however, few data exist to measure these modalities against each other or against no treatment at all. Endoscopic therapy for bleeding Mallory-Weiss lesions has included endoscopic electrocoagulation *(22)*, epinephrine injection *(23)*, or heater probe cauterization *(24)*. More recently, endoscopic band ligation similar to that used for bleeding esophageal varices has been utilized *(25,26)*. To date, however, no randomized, controlled trials have been performed to evaluate the efficacy of these modalities. Other modalities described in cases of failed endoscopic therapy include angiographic localization and embolization of the bleeding vessel *(27)*, which is a reasonable second-line approach. Placement of Sengstaken-Blakemore tube, although reported *(28)*, is no longer recommended for this condition

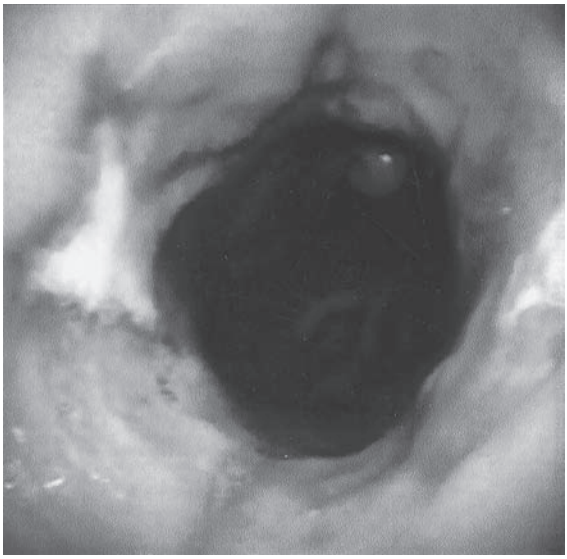

Fig. 2. Severe, erosive reflux esophagitis.

because of the substantial morbidity of the procedure itself. Surgery may be necessary to oversew the bleeding lesion if hemostasis cannot be achieved *(5,6,19,21)*. Although the efficacy of acid suppression in the treatment of Mallory-Weiss tears has not been studied, many patients are empirically placed on an antisecretory medicine *(21)*.

REFLUX ESOPHAGITIS

Gastroesophageal reflux disease (GERD) is a very common disorder, causing monthly symptoms in up to 36% of the U.S. population *(29)*. GERD occurs as a result of an abnormally prolonged exposure of the esophageal mucosa to gastric acid and pepsin. Reflux esophagitis occurs in a subset of patients with GERD in whom esophageal inflammation is visible as erosions or ulcerations (Fig. 2); it is found in 2–4% of the U.S. population *(30)*.

Reflux esophagitis is a common lesion of the upper GI tract found in the evaluation of GI bleeding. In a study of 248 patients with a mean age of 61 years who presented with positive fecal occult blood tests, esophagitis was detected in 9.3% and was the most common endoscopic abnormality *(31)*. In a separate study with a similar population, the same investigators found esophagitis to be one of the most common endoscopic abnormalities in patients presenting with iron deficiency anemia

(32). In several series, reflux esophagitis accounted for only 2–5% of all cases of acute upper GI bleeding, occurring less commonly than peptic ulcer disease (57–75%), esophageal varices (7–9%), or Mallory-Weiss tears *(19,20,33,34)*. However, in one recent study, reflux esophagitis accounted for 14.6% of overt upper GI tract bleeding *(35)*. The bleeding associated with acid reflux is not typically massive. In two large series, there were no deaths attributed to bleeding from reflux esophagitis *(19,20)*.

Although reflux esophagitis presenting as acute GI bleeding is uncommon in the general population, there are subgroups for which it poses an increased risk. In a study of 248 patients presenting with acute upper GI bleeding (115 aged > 80 and 133 aged 60–69 years), 21.1% of cases in patients older than 80 years were attributed to reflux esophagitis, compared with 3.3% of patients 60–69 years of age ($p < 0.001$) *(36)*. In another study, 25 critically ill patients underwent endoscopy at the time of endobronchial intubation and were re-endoscoped 5 days later *(37)*. They all had nasogastric tubes in place and were receiving intravenous H-2 receptor antagonists. After 5 days of mechanical ventilation, 48% had reflux esophagitis. Severity of esophagitis was related to the gastric residual volume. Critical illness, mechanical irritation from the nasogastric tube, disruption of the normal lower esophageal sphincter barrier by the presence of a nasogastric tube feeding in the supine position, and decreased gastric emptying are proposed mechanisms for the development of esophagitis in this population *(36,38)*. A case-control, retrospective review of institutionalized mentally retarded adults admitted for acute upper GI bleeding revealed reflux esophagitis to be the most common diagnosis, accounting for 70% of cases *(39)*.

Bleeding associated with reflux esophagitis is almost always self-limited, requiring no further interventions acutely beyond hemodynamic support, elimination of aggravating factors (i.e., NG tubes), and acid suppression to initiate healing. Proton pump inhibitors are superior to all other therapy in the healing of reflux esophagitis *(40)*. If the esophagitis is severe, the patient should begin high-dose proton pump inhibition, and repeat endoscopy in 8–12 weeks should be considered to assess healing and evaluate for the presence of Barrett's esophagus.

ESOPHAGEAL INFECTIONS

Infections of the esophagus rarely manifest in the general population, being more common among immunocompromised hosts. Viral, fungal, and bacterial infections of the esophagus typically present

with dysphagia and/or odynophagia rather than acute upper GI bleeding. Most of the published literature regarding acute upper GI bleeding secondary to esophageal infection is in the form of case reports or small series.

Viral Esophagitis

Herpes Simplex Virus

Herpes simplex virus (HSV) types 1 and 2 have each been reported to cause esophagitis *(41,42)*. The most common presentation is that of acute-onset odynophagia and dysphagia, retrosternal pain, and fever. Other presenting symptoms may include nausea, vomiting, or hematemesis. Lesions progress from fragile 1–3-mm vesicles predominantly in the mid-to-distal esophagus that slough, to sharply demarcated, "punched-out" ulcers with raised margins. These lesions may coalesce and form a larger area of ulceration. Heaped up inflammatory exudates may collect in the base of the ulcers in severe cases, resembling *Candida* esophagitis *(43)*. One case report described a black esophagus, suggesting necrosis and eschar formation *(44)*. Biopsies and brushings should be taken from the margin rather than the ulcer base to improve diagnostic yield since herpes infects the squamous epithelium. Biopsies should be taken for both histologic examination and culture, as this increases the diagnostic yield *(45,46)*. Although immunostaining is also available, its diagnostic yield may not exceed that of histology and culture combined *(46)*. Oral or parenteral acyclovir is the first-line agent used in treatment of HSV esophagitis.

In a review of 23 cases of HSV esophagitis, 30% were associated with acute upper GI bleeding *(45)*. There are no reports of specific endoscopic or radiographic treatments for bleeding HSV esophagitis. However, there is one report of a patient with massive bleeding that resolved after treatment with intravenous acyclovir *(47)*.

Presentation of herpes esophagitis in the immunocompetent host is similar to that of the immunocompromised patient, but it is less common and the course is typically less severe. In a retrospective review of 38 cases of HSV esophagitis in otherwise healthy hosts, 76% presented with odynophagia, 50% with heartburn, and 45% with fever *(46)*. Only 21% displayed concurrent oropharyngeal lesions. The endoscopic appearance was similar to that of immunocompromised hosts, including friability (84%), numerous ulcers (87%), distal esophageal distribution (64%), and whitish exudates (40%). Only 68% of histologic examinations detected characteristic findings, further demonstrating the need for concurrent viral cultures, which were positive in 96% of those tested. Immune serologies were consistent with primary infection in 21% of

cases. Although most cases were mild and self-limited, there was a report of acute hemorrhage and esophageal perforation.

Cytomegalovirus

Cytomegalovirus (CMV) esophagitis typically has a more subacute presentation than HSV esophagitis *(48)*. Initial symptoms such as weight loss, nausea, vomiting, fever, and diarrhea often reflect the more systemic nature of the infection. Odynophagia, dysphagia, or hematemesis may subsequently develop, alerting the clinician to the possibility of esophageal involvement. As with HSV, the distribution of lesions in CMV esophagitis is commonly in the mid-to-distal esophagus *(49)*. The ulceration is usually shallow, with flat margins, and may extend for several centimeters. However, in some cases deep ulcers may occur *(49)*. In contrast to HSV esophagitis, biopsies should be taken from the center of the ulcer for optimal results *(48)*. CMV produces intranuclear inclusion in macrophages that are not commonly detected in squamous epithelium. As with HSV, cultures in addition to histopathology increase the diagnostic yield of biopsies *(50)*. Gancyclovir is the first-line agent in the treatment of CMV esophagitis. Although rare, infections in immunocompetent individuals do occur *(51,52)*.

In a review of 33 patients with CMV esophagitis, 5 presented with acute upper GI bleeding *(49)*. In this study, 8% of all patients showed deep ulceration. There are also reported cases of CMV esophagitis causing massive GI hemorrhage necessitating emergent esophagectomy after failure of medical therapy *(53)*. There are no reports of either acute endoscopic or angiographic treatment of this condition.

Other Viral Infections

Other rare viral causes of bleeding esophageal lesions include varicella zoster virus, human papillomavirus, and human immunodeficiency virus (HIV) (Fig. 3) *(54,55)*. There are reports of isolation of HIV from esophageal ulcers in infected patients *(56)*, suggesting a pathologic role of the virus. However, the role of HIV in the development of esophageal ulceration is still unclear, as the presence of HIV in the esophageal mucosa is common and often is independent of esophageal pathology *(55,57)*.

Fungal Esophagitis

Candida Esophagitis

Candida albicans is a yeast that is found as part of the normal human oropharyngeal flora. It is a common cause of esophagitis in immunocompromised patients, including those with AIDS, or diabetes mellitus, those on immunosuppressive medications, and the elderly. Many

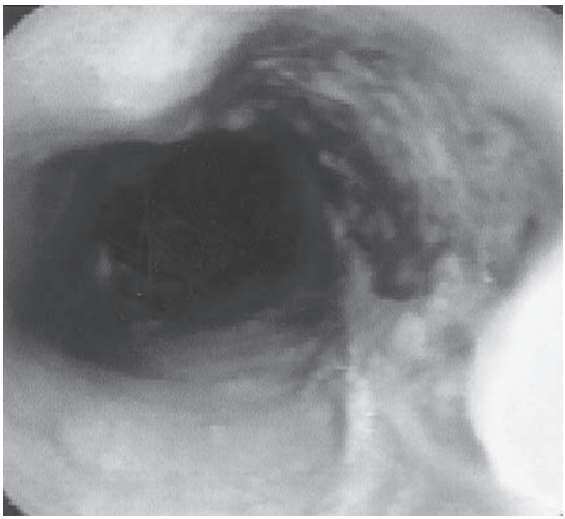

Fig. 3. Large, deep midesophageal ulceration in patient with AIDS. Viral cultures and histology did not reveal a pathogen or neoplasm consistent with an idiopathic HIV-related esophageal ulceration.

patients are asymptomatic, and infection is often found incidentally during investigation of another problem. Patients who are more immunosuppressed are typically more likely to be symptomatic, reflecting a more aggressive course of infection. The most common presenting symptoms are odynophagia or dysphagia. The endoscopic appearance of *C. albicans* esophagitis ranges from a few raised white plaques to confluent, elevated plaques with ulceration and buildup of "cottage cheese" material that may narrow the lumen *(58)*. Biopsies and brushings should be obtained for diagnosis; however, treatment is often empiric, based on endoscopic findings alone. Although oral thrush is a common finding, its absence should not rule out the diagnosis *(59,60)*.

Although rare, acute upper GI bleeding secondary to *C. albicans* esophagitis has been reported *(61)*. In one report, massive hemorrhage developed in a man with a history of renal failure *(62)*. In this patient, supportive care was continued until intravenous therapy with amphotericin B could initiate healing. In another, acute bleeding was noted in an alcoholic patient with esophageal ulcerations secondary to *C. albicans* in the setting of two epiphrenic diverticula *(63)*.

Other Fungal Infections

Blastomycosis dermatitidis is a rare cause of esophagitis and has been reported to cause acute upper GI bleeding *(64)*. *Histoplasma* spe-

cies are common pulmonary mycoses that may affect the esophagus by direct extension from the lung and mediastinum, or via hematogenous spread *(65)*. *Aspergillus* species are mycoses commonly affecting patients with underlying pulmonary disease. Although esophageal infection has been documented *(69)*, there are no reports of acute bleeding secondary to this pathogen. Treatment is supportive and includes antifungal therapy.

Bacterial Infections

Mycobacterium tuberculosis

Although *Mycobacterium tuberculosis* may infect any organ in the body, clinically significant esophageal involvement is rare. In immunocompromised cases, disseminated disease is common and can present with esophageal manifestations and symptoms that include dysphagia and chest pain. Esophageal infection may occur by hematogenous spread or direct extension from mediastinal lymph nodes. Endoscopically, the lesions appear as shallow ulcerations that range in size. Fistulae may be noted, as well as traction diverticula in the midesophagus secondary to scarring and retraction of mediastinal nodes *(70)*. Extrinsic compression may be seen as well *(71)*. Biopsies should be taken for routine histology, acid-fast smears, and mycobacterial culture.

There are several reports of acute upper GI bleeding from this condition, often secondary to fistulizing complications *(72–74)*. In a review of 11 patients with tuberculous esophagitis at a single institution over an 18-year period, two presented with hemorrhage *(70)*. When hemorrhage results from mucosal ulceration without fistula and is self-limited, medical management alone is reasonable.

Other Bacterial Infections

Rupture of a syphilitic aortic aneurysm into the esophagus of a patient resulting in massive hemorrhage and death has been reported *(75)*. Invasive bacterial esophagitis caused by normal oropharyngeal flora has been reported to occur in immunosuppressed patients, particularly in those with granulocytopenia *(76)*. Mucosal friability, pseudomembranes, and ulceration can be present *(76,77)* and may lead to bleeding, especially in the setting of a bleeding diathesis. Treatment with broad-spectrum antibiotics is generally sufficient.

MALIGNANT NEOPLASM

Malignant tumors of the esophagus, either primary or metastatic, are another cause of acute upper GI bleeding. Neovascularization as well as deep invasion of larger tumors can lead to such a complication. The most

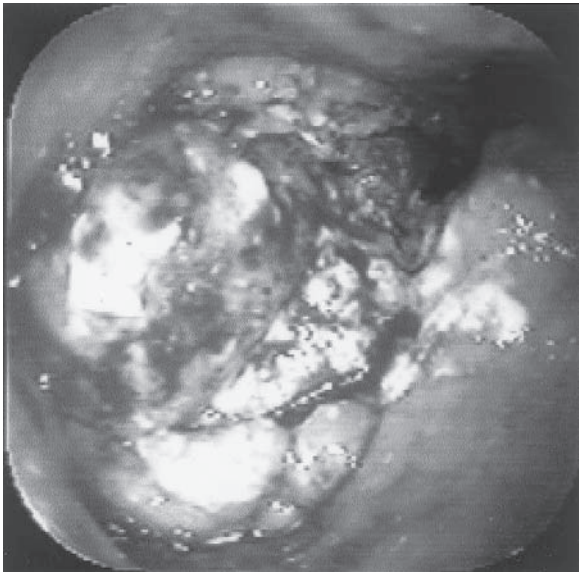

Fig. 4. Distal esophageal exophytic mass with biopsies revealing adenocarcinoma.

common primary malignancies of the esophagus are squamous cell carcinoma and adenocarcinoma, which account for more than 90% of all such lesions. Reports of rare primaries include malignant melanoma presenting as acute hemorrhage *(78)*, and esophageal stromal tumor typically presenting with dysphagia but rarely with acute bleeding *(79)*. Reported cases of bleeding from metastases include breast carcinoma *(80)*, renal cell carcinoma *(81)*, small cell carcinoma, osteogenic sarcoma, and germ cell tumors *(82)* (Table 1).

Endoscopically, esophageal carcinoma appears as a mucosal mass lesion that is often exophytic and ulcerated (Fig. 4). There are clinical characteristics of squamous cell carcinoma and adenocarcinoma, however, that may help influence clinical suspicion prior to the interpretation of biopsies. The most common site of squamous cell carcinoma is the midesophagus, whereas adenocarcinoma is frequently located in the distal esophagus. Although both cancers increase in incidence with age and male gender, specific risk factors for squamous cell carcinoma include African-American race and tobacco and alcohol use. Adenocarcinoma is more prevalent among Caucasians, with the primary risk factors being Barrett's esophagus and GERD. Although both are relatively uncommon cancers, the incidence of esophageal adenocarcinoma is rapidly increasing.

Esophageal carcinoma presenting as spontaneous acute upper GI bleeding is rare, with the dominant presenting symptom being dysphagia and weight loss. Large series have reported only rare cases of acute bleeding as the initial symptom *(19,20,34)*. There is a reported case of a distal esophageal carcinoma that penetrated the aorta, leading to fistula, massive hematemesis, and death *(83)*. In another case, a primary esophageal malignant melanoma presented with massive hematemesis *(78)*.

Acute bleeding in patients with esophageal carcinoma has been more commonly reported after treatment with radiation or metal stenting of the lesion. In a series of 423 consecutive patients with esophageal cancer treated with radiation therapy, 31 (7%) developed massive hemorrhage and died *(84)*. The mean interval from start of radiation until hemorrhage was 9.2 months. Risk factors included total dose exceeding 70 Gy, active infection, and metal stent placement. Eight of 22 patients (36%) receiving more than 80 Gy developed fatal massive hemorrhage. Prior chemotherapy and radiation were associated with acute upper GI bleeding that developed in 7/22 patients (32%) compared with 1/37 (3%) patients without prior treatment. An early report describes four patients who had recently completed radiation therapy for esophageal carcinoma that was complicated by fatal hemorrhage; two of the patients developed aortoesophageal fistulae *(85)*. In contrast, another retrospective study of 60 cases reported no increased risk of life-threatening complications after chemotherapy or radiation *(86)*. Although it is intuitive that radiation or chemotherapy increases tissue destruction, potentially increasing the likelihood of hemorrhage, the natural history of esophageal tumors in the absence of metal stenting or radiation is poorly defined. Stenting an obstructing cancer might allow the tumor to progress to the point where it would have bled even in the absence of stenting.

No large series have examined the efficacy of therapeutic modalities in the treatment of acutely bleeding esophageal carcinoma. Cases of ethanol injection *(87)* and selective arteriography with embolization *(88)* have been reported. In a small series examining the use of argon-plasma coagulation, bleeding was controlled successfully in three of five cases *(89)*. The use of endoscopic laser devices has been reported for palliation of obstructing cancers *(90,91)*, although its effectiveness for bleeding has not been reported. Novel technologies such as endoscopic cryotherapy *(92)* are currently being studied.

MISCELLANEOUS CONDITIONS

Esophageal Dieulafoy's Lesion

Dieulafoy's lesion is an abnormal submucosal artery in the GI tract characterized by recurrent episodes of acute gastrointestinal hemor-

rhage. The most common location is the proximal stomach, where the lesion appears as a reddish protuberance within normal mucosa. Its appearance is subtle; without active bleeding on endoscopy, it may be missed altogether. Extragastric Dieulafoy's lesions are rare but have been reported, in the esophagus *(93,94)*. Epinephrine injection *(95)* and endoscopic band ligation *(96)* have been reported as successful treatment options in the management of esophageal Dieulafoy's lesions.

Iatrogenic Causes

Several iatrogenic causes have been reported as causes of esophageal bleeding (Table 1). Bleeding may complicate routine endoscopic procedures, but more commonly it is a complication of therapeutic endoscopy. Such procedures include esophageal variceal sclerotherapy or banding, esophageal biopsies, photodynamic therapy, and dilation. Bleeding is a well-recognized albeit rare complication of all forms of esophageal dilation including mercury bougienage (Maloney dilators), polyvinyl dilators (Savary-Guillard), and balloon dilators. Most studies report a risk of bleeding of less than 0.5% with esophageal dilation.

The relationship of nasogastric intubation and GERD in the development of esophagitis has already been discussed. However, independent of acid reflux, the presence of a nasogastric tube itself may lead to significant esophageal erosions over time *(37,97)*. These lesions, secondary to mechanical trauma, are more likely to be located in the proximal esophagus and appear to be linear in nature. If possible, the nasogastric tube should be removed. There are reports of vascular esophageal fistula development causing massive hemorrhage secondary to nasogastric tube use, but this complication is very rare *(98)*.

Systemic chemotherapy may lead to mucositis involving the entire GI tract, including the esophagus. Mucositis is a common side effect of standard chemotherapeutic regimens, as well as those used in bone marrow transplantation. Agents that predispose to this condition include dactinomycin, bleomycin, cytarabine, daunorubicin, vincristine, 5-fluorouracil, and methotraxate. Esophageal injury usually begins to occur shortly after blood counts reach their nadir. The esophageal mucosa becomes friable and may slough or ulcerate. Bleeding can occur, particularly in patients who are thrombocytopenic. The mucositis may be severe but is usually self-limited. It is important to differentiate between this and infectious etiologies, as patients receiving chemotherapy are immunocompromised and are therefore at risk for opportunistic infection. It is rare to have esophageal involvement secondary to chemotherapy without oropharyngeal involvement, and odynophagia is likely to be present. When significant bleeding occurs, support with

blood products including platelets should be continued until the condition resolves. This may take several days and usually commences when blood counts begin to recover.

Radiation therapy to the chest may lead to acute esophageal injury. Acute radiation esophagitis typically occurs 2–3 weeks after initiating therapy, with erosions and ulcerations that may persist for several weeks after its conclusion. Chest pain and dysphagia are common associated symptoms. The severity of esophagitis is related to the dose of radiation. At doses greater than 40 Gy, edema and redness become more frequent; moderate to severe esophagitis becomes more likely as the dose nears 60–70 Gy *(99,100)*. Concomitant chemotherapy potentiates radiation damage, and significant esophagitis may be seen with as little as 25 Gy *(101)*. Although some studies report success in improving symptoms and severity of radiation esophagitis with sucralfate *(102)*, others have not reproduced these results *(103)*.

Graft-versus-host disease (GvHD), most commonly seen after bone marrow transplantation, may involve the esophagus and may present with dysphagia, odynophagia, or chest pain. Chronic GvHD seen weeks to months after transplantation involves the esophagus more extensively than does acute GvHD *(104)*. Endoscopy may reveal generalized friability and desquamation in the esophagus. Severe cases may lead to esophageal bleeding or stricture formation dilation *(105)*. Treatment includes immunosuppressive medications such as glucocorticoids or azathioprine.

Drug toxicity may take several forms in the GI tract, including Stevens-Johnsons syndrome, a desquamating condition that may occur secondary to therapy with many drugs, most commonly antibiotics such as penicillins or sulfa-based products. Diffuse GI ulceration and sloughing may occur, leading to melena, hematochezia, or hematemesis. Extensive necrosis with lymphocytic infiltration and apoptosis occurs; lesions are histologically similar to those seen in chronic GvHD. Supportive care and withdrawal of offending agents is the mainstay of management. Use of immunosuppressive agents is controversial for early disease, and these are generally not helpful for advanced disease *(106)*.

Pill Esophagitis and Caustic Ingestion

Pill esophagitis has been reported after the use of multiple medications including NSAIDS, tetracycline, erythromycin, potassium chloride, and bisphosphonates. Typically presenting with acute onset of odynophagia, the lesions are ulcers caused by direct toxicity to esophageal mucosa by pills that may fail to clear the esophagus normally during swallowing. The ulcers may be deep and extensive, and they

Fig. 5. Midesophageal ulceration in a patient presenting with odynophagia and a history of ingestion of tetracycline.

usually occur in the midesophagus (Fig. 5). Although cases are most often self-limited, complications that include hemorrhage, stricture, and perforation can occur *(107)*. Care should be taken to evaluate for signs of perforation by monitoring vital signs, examination for crepitus in the chest and neck, and chest radiograph if doubt persists. Patients should be encouraged to sit upright and take an adequate amount of fluid with pills to minimize the risk of this condition. Topical agents such as sucralfate or lidocaine are sometimes used for symptomatic relief, although there are no data on their efficacy. Endoscopic evaluation is recommended when the diagnosis of pill esophagitis is uncertain or in cases of significant hemorrhage.

Ingestion of strongly acid or alkaline solutions may lead to rapid and severe esophageal injury. Alkali injury leads to liquefaction necrosis and deeper injury than the coagulation necrosis associated with acid ingestion. The mucosa may become friable or deeply ulcerated and may perforate in severe cases. Esophageal injury may be present in the absence of oral lesions *(108)*. Dysphagia, odynophagia, hematemesis, hoarseness, or stridor may develop. Optimal timing of endoscopy is controversial; endoscopy is contraindicated if suspicion of perforation exists. If the esophagus appears erythematous or displays nonconfluent

ulceration, supportive care and observation are adequate. The presence of circumferential lesions or deep ulcers with eschar formation is more predictive of subsequent stricture formation, and follow-up endoscopy should be performed regularly to assess for stricturing. Over time, repeated dilation may be necessary. Glucocorticoids, once thought to be beneficial in prevention of strictures, are no longer used. In the absence of suspicion of perforation, antibiotics are generally not indicated. Neutralization of the substance should never be performed because the resultant heat production may add further thermal injury to the already injured tissue. Carcinoma of the esophagus is a late complication of lye ingestion, with a 1000–3000-fold increase in the incidence of squamous cell carcinoma of the esophagus; the average interval is 40 years after ingestion *(109)*.

Systemic Inflammatory Disorders

Crohn's disease rarely involves the esophagus *(110)*. Associated lesions include aphthous lesions, inflammatory strictures, fistulae, polyps, and large ulcers. Although these lesions may bleed acutely, there are no reported cases of acute upper GI bleeding attributed to Crohn's disease isolated to the esophagus, perhaps because of the exceedingly rare nature of this complication. Treatment with topical agents is often ineffective owing to the proximal distribution of the disease. Systemic immunomodulatory agents may be necessary to control Crohn's disease of the esophagus.

Several systemic cutaneous disorders may lead to diffuse esophageal involvement. Epidermolysis bullosa comprises several rare disorders in which blister formation occurs after minor trauma. Dysphagia, pain, and bleeding may result *(111)*. Pemphigus vulgaris is an autoimmune disorder in which large bullae form spontaneously, commonly affecting the esophagus. Esophageal bleeding is less common yet possible in bullous pemphigoid, a chronic disease characterized by bulla formation and circulating autoantibodies to the basement membrane. Corticosteroids are used in the management of all these disorders. Stricturing is possible, and dilation may be necessary *(111,112)*.

Esophagitis secondary to collagen vascular diseases has been reported, including Wegener's granulomatosis and anticardiolipin antibody syndrome *(113,114)*. Reflux esophagitis may complicate scleroderma owing to poor peristaltic activity of the esophageal smooth muscle and hypotension of the lower esophageal sphincter. Treatment is based on the specific disorder.

Hemangioma

Hemangioma of the esophagus has been reported as a rare cause of acute esophageal bleeding *(115)*. There is also a report of recurrent

massive acute upper GI bleeding attributed to a vagal neurilemoma diagnosed at thoracotomy *(116)*. When possible, endoscopic therapy should be attempted. If bleeding persists, surgical intervention may be necessary.

Esophagoarterial Fistula

Esophagoaortic fistulae formations in the setting of esophageal carcinoma or nasogastric intubation have already been discussed. There has been a single report of esophagoaortic fistula presenting with massive bleeding attributed to reflux esophagitis *(117)*. There is also a report of periesophageal abscess leading to esophagoaortic fistula formation and massive bleeding *(118)*. Esophageal foreign body ingestion may lead to fistula formation in vascular structures of the chest. Impaction of a fishbone in the esophagus has led to fistula formation in the subclavian artery *(119)*. There are several reports of foreign body ingestion by children and adults that have caused esophagoaortic fistula formation *(120,121)*. Management is surgical, as bleeding is often life-threatening and not amenable to endoscopic management.

CONCLUSIONS

Nonvariceal esophageal bleeding is a common cause of acute upper GI hemorrhage. The differential diagnosis of nonvariceal esophageal bleeding is large, and the condition often requires endoscopy for accurate diagnosis. In general, the more common causes of acute esophageal hemorrhage are self-limited or respond to conservative management. Massive, acute bleeding, however, does occur. Prompt diagnosis is important, as the treatments of the various disorders are quite diverse and include medical, endoscopic, and surgical management.

REFERENCES

1. Bharucha AE, Gostout CJ, Balm RK. Clinical and endoscopic risk factors in the Mallory-Weiss syndrome. Am J Gastroenterol 1997; 92: 805–808.
2. Graham DY, Schwartz JT. The spectrum of the Mallory-Weiss tear. Medicine (Balti) 1978; 57: 307–318.
3. Bubrick MP, Lundeen JW, Hitchcock JR. Mallory-Weiss syndrome: analysis of fifty-nine cases. Surgery 1980; 88: 400–405.
4. Hastings PR, Peters KW, Cohn I Jr. Mallory-Weiss syndrome. Review of 69 cases. Am J Surg 1981; 142: 560–562.
5. Knauer CM. Mallory-Weiss syndrome. Characterization of 75 Mallory-weiss lacerations in 528 patients with upper gastrointestinal hemorrhage. Gastroenterology 1976; 71: 5–8.
6. Sugawa C, Benishek D, Walt AJ. Mallory-Weiss syndrome. A study of 224 patients. Am J Surg 1983; 145: 30–33.

7. Hellers G, et al. The Mallory-Weiss syndrome. A review of 23 cases with special reference to coagulation defects. Acta Chir Scand Suppl 1978; 482: 9–11.
8. Clain JE, Novis BH, Barbezat GO, Bank S. The Mallory-Weiss syndrome. A prospective study in 130 patients. S Afr Med J 1978; 53: 596–597.
9. Hixson SD, Burns RP, Britt LG. Mallory-Weiss syndrome: retrospective review of eight years' experience. South Med J 1979; 72: 1249–1251.
10. Annunziata GM, Gunasekaran TS, Berman JH, Kraut JR. Cough-induced Mallory-Weiss tear in a child. Clin Pediatr (Phila) 1996; 35: 417–419.
11. Cappell MS, Sidhom O. A multicenter, multiyear study of the safety and clinical utility of esophagogastroduodenoscopy in 20 consecutive pregnant females with follow-up of fetal outcome. Am J Gastroenterol 1993; 88: 1900–1905.
12. Hroncich ME. Mallory Weiss tears due to colonoscopy preps. Am J Gastroenterol 1994; 89: 292.
13. Montalvo RD, Lee M. Retrospective analysis of iatrogenic Mallory-Weiss tears occurring during upper gastrointestinal endoscopy. Hepatogastroenterology 1996; 43: 174–177.
14. Norfleet RG, Smith GH. Mallory-Weiss syndrome after cardiopulmonary resuscitation. J Clin Gastroenterol 1990; 12: 569–572.
15. Penston JG, Boyd EJ, Wormsley KG. Mallory-Weiss tears occurring during endoscopy: a report of seven cases. Endoscopy 1992; 24: 262–265.
16. Michel L, Serrano A, Malt RA. Mallory-Weiss syndrome. Evolution of diagnostic and therapeutic patterns over two decades. Ann Surg 1980; 192: 716–721.
17. Kerlin P, Bassett D, Grant AK, Paull A. The Mallory-Weiss lesion: a five-year experience. Med J Aust 1978; 1: 471–473.
18. Watts HD. Lesions brought on by vomiting: the effect of hiatus hernia of the site of injury. Gastroenterology 1976; 71: 683–688.
19. Sereda S, Lamont I, Hunt P. The experience of a haematemesis and melaena unit: a review of the first 513 consecutive admissions. Med J Aust 1977; 1: 362–366.
20. Sugawa C, Steffes CP, Nakamura R, et al. Upper GI bleeding in an urban hospital. Etiology, recurrence, and prognosis. Ann Surg 1990; 212: 521–526; discussion 526–527.
21. Harris JM, DiPalma JA. Clinical significance of Mallory-Weiss tears. Am J Gastroenterol 1993; 88: 2056–2058.
22. Papp JP. Electrocoagulation of actively bleeding Mallory-Weiss tears. Gastrointest Endosc 1980; 26: 128–130.
23. Curran D, Sweeten M, Frommer D. Endoscopic application of noradrenaline for Mallory-Weiss bleeding. Lancet 1980; 1: 538.
24. Himal HS. Endoscopic control of upper gastrointestinal bleeding. Can J Surg 1985; 28: 305–308.
25. Abi-Hanna D, Williams SJ, Gillespre PE, Bourke MJ. Endoscopic band ligation for non-variceal non-ulcer gastrointestinal hemorrhage. Gastrointest Endosc 1998; 48: 510–514.
26. Myung SJ, Kim HR, Moon YS. Severe Mallory-Weiss tear after endoscopy treated by endoscopic band ligation. Gastrointest Endosc 2000; 52: 99–101.
27. Lieberman DA, Keller FS, Katon RM, Rosch J. Arterial embolization for massive upper gastrointestinal tract bleeding in poor surgical candidates. Gastroenterology 1984; 86: 876–885.
28. Knoblauch M, Stevka E, Lammli J, et al. The Mallory-Weiss-syndrome: a clinical study of 20 cases. Endoscopy 1976; 8: 5–9.
29. Nebel OT, Fornes MF, Castell DO. Symptomatic gastroesophageal reflux: incidence and precipitating factors. Am J Dig Dis 1976; 21: 953–956.

30. Sonnenberg A, El-Serag HB. Clinical epidemiology and natural history of gastroesophageal reflux disease. Yale J Biol Med 1999; 72: 81–92.
31. Rockey DC, Koch J, Cello JP, Sanders LL, McQuard K. Relative frequency of upper gastrointestinal and colonic lesions in patients with positive fecal occult-blood tests. N Engl J Med 1998; 339: 153–159.
32. Rockey DC, Cello JP. Evaluation of the gastrointestinal tract in patients with iron-deficiency anemia. N Engl J Med 1993; 329: 1691–1695.
33. Webb WA, McDaniel L, Johnson RC, Haymes CD. Endoscopic evaluation of 125 cases of upper gastrointestinal bleeding. Ann Surg 1981; 193: 624–627.
34. Wilcox CM, Clark WS. Causes and outcome of upper and lower gastrointestinal bleeding: the Grady Hospital experience. South Med J 1999; 92: 44–50.
35. Costa ND, Cadiot G, Merle C, et al. Bleeding reflux esophagitis: a prospective 1-year study in a university hospital. Am J Gastroenterol 2001; 96: 47–51.
36. Zimmerman J, Shohat V, Tsvang E, Amon R, Safadi R, Wengrower D. Esophagitis is a major cause of upper gastrointestinal hemorrhage in the elderly. Scand J Gastroenterol 1997; 32: 906–909.
37. Wilmer A, Tack J, Frans E, et al. Duodenogastroesophageal reflux and esophageal mucosal injury in mechanically ventilated patients. Gastroenterology 1999; 116: 1293–1299.
38. Newton M, Burnham WR, Kamm MA. Morbidity, mortality, and risk factors for esophagitis in hospital inpatients. J Clin Gastroenterol 2000; 30: 264–269.
39. Orchard JL, Stramat J, Wolfgang M, Trimpey A. Upper gastrointestinal tract bleeding in institutionalized mentally retarded adults. Primary role of esophagitis. Arch Fam Med 1995; 4: 30–33.
40. Kahrilas PJ. Gastroesophageal reflux disease. JAMA 1996; 276: 983–988.
41. Nash G, Ross JS. Herpetic esophagitis. A common cause of esophageal ulceration. Hum Pathol 1974; 5: 339–345.
42. Wandl-Hainberger I, et al. [Ulcerative herpes simplex virus II esophagitis]. ROFO Fortschr Geb Rontgenstr Nuklearmed 1988; 148: 215–216.
43. Byard RW, Champion MC, Orizaga M. Variability in the clinical presentation and endoscopic findings of herpetic esophagitis. Endoscopy 1987; 19: 153–155.
44. Cattan P, Cuillerier E, Cellier C, et al. Black esophagus associated with herpes esophagitis. Gastrointest Endosc 1999; 49: 105–107.
45. McBane RD, Gross JB Jr. Herpes esophagitis: clinical syndrome, endoscopic appearance, and diagnosis in 23 patients. Gastrointest Endosc 1991; 37: 600–603.
46. Ramanathan J, Rammouni M, Baran J Jr, Khutib R. Herpes simplex virus esophagitis in the immunocompetent host: an overview. Am J Gastroenterol 2000; 95: 2171–2176.
47. Rattner HM, Cooper DJ, Zaman MB. Severe bleeding from herpes esophagitis. Am J Gastroenterol 1985; 80: 523–525.
48. Baehr PH, McDonald GB. Esophageal infections: risk factors, presentation, diagnosis, and treatment. Gastroenterology 1994; 106: 509–532.
49. Wilcox CM, Straub RF, Schwartz DA. Prospective endoscopic characterization of cytomegalovirus esophagitis in AIDS. Gastrointest Endosc 1994; 40: 481–484.
50. Hackman RC, Wolford JL, Gleaves CA, et al. Recognition and rapid diagnosis of upper gastrointestinal cytomegalovirus infection in marrow transplant recipients. A comparison of seven virologic methods. Transplantation 1994; 57: 231–237.
51. Venkataramani A, Schueter AJ, Speech JJ, Greenberg F. Cytomegalovirus esophagitis in an immunocompetent host. Gastrointest Endosc 1994; 40: 392–393.
52. Altman C, Bedossa P, Dussaix E, Buffet C. Cytomegalovirus infection of esophagus in immunocompetent adult. Dig Dis Sci 1995; 40: 606–608.

53. Featherstone RJ, Camero LG, Khatib R, Shower D, Mungara P. Massive esophageal bleeding in achalasia complicated by cytomegalovirus esophagitis. Ann Thorac Surg 1995; 59: 1021–1022.
54. Schechter M, Pannain VL, de Oliveira AV. Papovavirus-associated esophageal ulceration in a patient with AIDS. AIDS 1991; 5: 238.
55. Smith PD, Eisner MS, Manischewitz JF, Gill VJ, Masur H, Fox CF. Esophageal disease in AIDS is associated with pathologic processes rather than mucosal human immunodeficiency virus type 1. J Infect Dis 1993; 167: 547–552.
56. Rabeneck L, Popovic M, Gartner S, et al. Acute HIV infection presenting with painful swallowing and esophageal ulcers. JAMA 1990; 263: 2318–2322.
57. Gill MJ, Sutherland LR, Church DL. Gastrointestinal tissue cultures for HIV in HIV-infected/AIDS patients. The University of Calgary Gastrointestinal/HIV Study Group. Aids 1992; 6: 553–556.
58. Kodsi BE, Wickremesinghe C, Kozinn PJ, Iswara K, Goldberg PK. *Candida* esophagitis: a prospective study of 27 cases. Gastroenterology 1976; 71: 715–719.
59. Antinori A, Antinori A, Ammassari A, et al. Presumptive clinical criteria versus endoscopy in the diagnosis of *Candida* esophagitis at various HIV-1 disease stages. Endoscopy 1995; 27: 371–376.
60. Wilcox CM, Karowe MW. Esophageal infections: etiology, diagnosis, and management. Gastroenterologist 1994; 2: 188–206.
61. Kaplan D, Warren J. Massive gastrointestinal hemorrhage due to *Candida* esophagitis. Am J Gastroenterol 1988; 83: 463–464.
62. Kumar A. Massive upper gastrointestinal bleeding due to *Candida* esophagitis. South Med J 1994; 87: 669–671.
63. Hoxie DA, Dillon MC, Tuckson WB, Desal RM. Profuse bleeding in epiphrenic diverticula: an unusual finding. J Natl Med Assoc 1995; 87: 373–375.
64. McKenzie R, Khakoo R. Blastomycosis of the esophagus presenting with gastrointestinal bleeding. Gastroenterology 1985; 88: 1271–1273.
65. Lee JH, Neumann DA, Welsh JD. Disseminated histoplasmosis presenting with esophageal symptomatology. Am J Dig Dis 1977; 22: 831–834.
66. Forsmark CE, Wilcox CM, Darragh TM, Cello JP. Disseminated histoplasmosis in AIDS: an unusual case of esophageal involvement and gastrointestinal bleeding. Gastrointest Endosc 1990; 36: 604–605.
67. Kefri M, Dyke S, Copeland S, Morgan CV Jr, Menta JB. Hemoptysis and hematemesis due to a broncholith: granulomatous mediastinitis. South Med J 1996; 89: 243–245.
68. Tucker LE, Aquino T, Sasser W. Mid-esophageal traction diverticulum: rare cause of massive upper gastrointestinal bleeding. MO Med 1994; 91: 140–142.
69. Obrecht WF Jr, Richter JE, Olympio GA, Belfand DW. Tracheoesophageal fistula: a serious complication of infectious esophagitis. Gastroenterology 1984; 87: 1174–1179.
70. Mokoena T, Shama DM, Ngakane H, Bryer JV. Oesophageal tuberculosis: a review of eleven cases. Postgrad Med J 1992; 68: 110–115.
71. Barcena R, Erdozain JC, Lopez-San Roman A. Tuberculous mediastinal adenopathy mimicking esophageal leiomyoma. Endoscopy 1990; 22: 57–58.
72. Newman RM, Fleshner PR, Lajam FE, Kim U. Esophageal tuberculosis: a rare presentation with hematemesis. Am J Gastroenterol 1991; 86: 751–755.
73. Chase RA, Haber MH, Pottage JC Jr, Schaffner JA, Miller C, Levin S. Tuberculous esophagitis with erosion into aortic aneurysm. Arch Pathol Lab Med 1986; 110: 965–966.

74. O'Leary M, Nollet DJ, Blomberg DJ. Rupture of a tuberculous pseudoaneurysm of the innominate artery into the trachea and esophagus: report of a case and review of the literature. Hum Pathol 1977; 8: 458–467.
75. Zagrebin VM, Fomin SD. [A rare case of rupture of a syphilitic aortic aneurysm into the esophagus]. Ter Arkh 1988; 60: 70–71.
76. Walsh TJ, Belitsos NJ, Hamilton SR. Bacterial esophagitis in immunocompromised patients. Arch Intern Med 1986; 146: 1345–1348.
77. Ezzell JH Jr, Bremer J, Adamec TA. Bacterial esophagitis: an often forgotten cause of odynophagia. Am J Gastroenterol 1990; 85: 296–298.
78. Yoshikane H, et al. Primary malignant melanoma of the esophagus presenting with massive hematemesis. Endoscopy 1995; 27: 397–399.
79. Hatch GF 3rd, Wertheimer-Hatch L, Hatch KF, et al. Tumors of the esophagus. World J Surg 2000; 24: 401–411.
80. Hastier P, Francois E, Delmont JP, Harris AG, Barthel HR, Namer M. Esophageal metastases from breast cancer detected by hematemesis. Am J Gastroenterol 1994; 89: 289–290.
81. Nussbaum M, Grossman M. Metastases to the esophagus causing gastrointestinal bleeding. Am J Gastroenterol 1976; 66: 467–472.
82. Kadakia SC, Parker A, Canales L. Metastatic tumors to the upper gastrointestinal tract: endoscopic experience. Am J Gastroenterol 1992; 87: 1418–1423.
83. Shimizu M, Itoh H, Matsuzaki T, Yano M. Lower-third esophageal cancer penetrating the aorta: sudden death after emergency admission in a nontreated patient. Am J Gastroenterol 1989; 84: 1129–1130.
84. Nemoto, K, Takai Y, Ogawa Y, et al. Fatal hemorrhage in irradiated esophageal cancer patients. Acta Oncol 1998; 37: 259–262.
85. Alrenga DP. Fatal hemorrhage complicating carcinoma of the esophagus. Report of four cases. Am J Gastroenterol 1976; 65: 422–426.
86. Raijman I, Siddique I, Lynch P. Does chemoradiation therapy increase the incidence of complications with self-expanding coated stents in the management of malignant esophageal strictures? Am J Gastroenterol 1997; 92: 2192–2196.
87. Loscos JM, Calvo E, Alvarez-Sala JL, Espinos D. Treatment of dysphagia and massive hemorrhage in esophageal carcinoma by ethanol injection. Endoscopy 1993; 25: 544.
88. Kos X, Trotteur G, Dondelinger RF. Delayed esophageal hemorrhage caused by a metal stent: treatment with embolization. Cardiovasc Intervent Radiol 1998; 21: 428–430.
89. Akhtar K, Byrne JP, Bancewic ZJ, Attwood SE. Argon beam plasma coagulation in the management of cancers of the esophagus and stomach. Surg Endosc 2000; 14: 1127–1130.
90. Tranberg KG, Stael von Holstein C, Ivancev K, Cwikiel W, Lunderquist A. The YAG laser and Wallstent endoprosthesis for palliation of cancer in the esophagus or gastric cardia. Hepatogastroenterology 1995; 42: 139–144.
91. Rutgeerts P, Vantrappen G, Broeckaert L, et al. Palliative Nd:YAG laser therapy for cancer of the esophagus and gastroesophageal junction: impact on the quality of remaining life. Gastrointest Endosc 1988; 34: 87–90.
92. Pasricha PJ, Hill S, Wadwa KS, et al. Endoscopic cryotherapy: experimental results and first clinical use. Gastrointest Endosc 1999; 49: 627–631.
93. Anireddy D, Timberlake G, Seibert D. Dieulafoy's lesion of the esophagus. Gastrointest Endosc 1993; 39: 604.
94. Scheider DM, Barthel JS, King PD, Beale GD. Dieulafoy-like lesion of the distal esophagus. Am J Gastroenterol 1994; 89: 2080–2081.

95. Jaspersen D, Komer T, Schorr W, Brennenstuhl M, Hammar CH. Extragastric Dieulafoy's disease as unusual source of intestinal bleeding. Esophageal visible vessel. Dig Dis Sci 1994; 39: 2558–2560.
96. Soetikno RM, Piper J, Montes H, Ukomadu C, Carr-Locke DL. Use of endoscopic band ligation to treat a Dieulafoy's lesion of the esophagus. Endoscopy 2000; 32: S15.
97. Baccino E, Boles JM, Le Guillou M, et al. [Attempt at preventive treatment of esophagitis caused by intubation during intensive care]. Gastroenterol Clin Biol 1987; 11: 24–28.
98. Minyard AN, Smith DM. Arterial-esophageal fistulae in patients requiring nasogastric esophageal intubation. Am J Forensic Med Pathol 2000; 21: 74–78.
99. Mascarenhas F, Silvestre ME, Sadacosta M, Grima N, Campos C, Chaves P. Acute secondary effects in the esophagus in patients undergoing radiotherapy for carcinoma of the lung. Am J Clin Oncol 1989; 12: 34–40.
100. Saunders MI, Dische S. Continuous, hyperfractionated, accelerated radiotherapy (CHART) in non-small cell carcinoma of the bronchus. Int J Radiat Oncol Biol Phys 1990; 19: 1211–1215.
101. Umsawasdi T, Valdivieso M, Barkley HT, et al. Esophageal complications from combined chemoradiotherapy (cyclophosphamide + Adriamycin + cisplatin + XRT) in the treatment of non-small cell lung cancer. Int J Radiat Oncol Biol Phys 1985; 11: 511–519.
102. Sur RK, Kochhar R, Singh DP. Oral sucralfate in acute radiation oesophagitis. Acta Oncol 1994; 33: 61–63.
103. McGinnis WL, Loprinzi CL, Buskirk SJ, et al. Placebo-controlled trial of sucralfate for inhibiting radiation-induced esophagitis. J Clin Oncol 1997; 15: 1239–1243.
104. McDonald GB, Sullivan KM, Schuffler MD, Shulman HM, Thomas ED. Esophageal abnormalities in chronic graft-versus-host disease in humans. Gastroenterology 1981; 80: 914–921.
105. McDonald GB, Sullivan KM, Plumley TF. Radiographic features of esophageal involvement in chronic graft-vs.-host disease. AJR Am J Roentgenol 1984; 142: 501–506.
106. Roujeau JC. Treatment of severe drug eruptions. J Dermatol 1999; 26: 718–722.
107. Kikendall JW. Pill esophagitis. J Clin Gastroenterol 1999; 28: 298–305.
108. Ray JF 3rd, Myers WO, Lawton BR, Lee FY, Wenzel FJ, Sautter RD. The natural history of liquid lye ingestion. Rationale for aggressive surgical approach. Arch Surg 1974; 109: 436–439.
109. Appelqvist P, Salmo M. Lye corrosion carcinoma of the esophagus: a review of 63 cases. Cancer 1980; 45: 2655–2658.
110. Rudolph I, Goldstein F, DiMarino AJ Jr. Crohn's disease of the esophagus: three cases and a literature review. Can J Gastroenterol 2001; 15: 117–122.
111. Ergun GA, Lin AN, Dannenberg AJ, Carter DM. Gastrointestinal manifestations of epidermolysis bullosa. A study of 101 patients. Medicine (Balti) 1992; 71: 121–127.
112. Braghetto I, Cortes C. Upper esophageal stricture secondary to dermatologic bullous disorders: a case report and review of the literature. Dis Esophagus 1998; 11: 198–201.
113. Spiera RF, Filippa DA, Bains MS, Paget SA. Esophageal involvement in Wegener's granulomatosis. Arthritis Rheum 1994; 37: 1404–1407.
114. Cappell MS. Esophageal necrosis and perforation associated with the anticardiolipin antibody syndrome. Am J Gastroenterol 1994; 89: 1241–1245.

115. Taylor FH, et al. Hemangioma of the esophagus. Ann Thorac Surg 1996; 61: 726–728.
116. DeVault KR, Miller LS, Yaghsezian H, et al. Acute esophageal hemorrhage from a vagal neurilemoma. Gastroenterology 1992; 102: 1059–1061.
117. Cronen P, Snow N, Nightingale D. Aortoesophageal fistula secondary to reflux esophagitis. Ann Thorac Surg 1982; 33: 78–80.
118. Sigalet DL, Laberge JM, DiLorenzo M, et al. Aortoesophageal fistula: congenital and acquired causes. J Pediatr Surg 1994; 29: 1212–1214.
119. Loh KS, Tan KK. Subclavian-oesophageal fistula as a complication of foreign body ingestion: a case report. Ann Acad Med Singapore 1998; 27: 277–278.
120. Jiraki K. Aortoesophageal conduit due to a foreign body. Am J Forensic Med Pathol 1996; 17: 347–348.
121. Wu MH, Lai WW. Aortoesophageal fistula induced by foreign bodies. Ann Thorac Surg 1992; 54: 155–156.