

Preface

More than half of the first volume of *Chassin's Operative Strategy in General Surgery*, introduced in 1980, was devoted to surgery of the small and large intestine and anorectum. This unusually rich and detailed coverage was maintained and even expanded in subsequent editions. The “big” Chassin's has become an invaluable resource for the surgical community.

In recent years, colorectal surgery has become a specialty unto itself, practiced by both colorectal and general surgeons. This volume, *Chassin's Operative Strategy in Colon and Rectal Surgery*, seek to provide the gold standard content of the large volume with the focus and specificity needed by colorectal surgeons. Practiced clinicians, fellows, and residents will all find valuable clinical guidance in these chapters.

Colorectal surgery is a rapidly-evolving surgical field. Since the last edition of the full volume of Chassin's, laparoscopic colon surgery has become the new standard of care for many patients. Thus, we have added four new, previously unpublished chapters to this new volume:

- laparoscopic right hemicolectomy
- laparoscopic left hemicolectomy
- laparoscopic abdominoperineal resection and total proctocolectomy with end ileostomy
- laparoscopic stoma construction and closure

Written by Steven D. Wexner, these new chapters provide the reader with the latest techniques in colorectal surgery. In addition to the clear, comprehensive text, these new chapters are enhanced by 52 lavish new illustrations by Caspar Henselmann, the skilled artist whose work has illuminated every edition of this text.

It is our hope that the reader will find *Chassin's Operative Strategy in Colon and Rectal Surgery* a useful distillation of the best of the “old” and the “new” strategies and techniques in colorectal surgery.

Carol E.H. Scott-Conner, MD, PhD

2 Right Colectomy for Cancer

INDICATIONS

Malignancy of the ileocecal region, ascending colon, and transverse colon

PREOPERATIVE PREPARATION

Colonoscopy to confirm the diagnosis and exclude other pathology

Computed tomography (CT) of abdomen

Mechanical and antibiotic bowel preparation

Perioperative antibiotics

PITFALLS AND DANGER POINTS

Injury or inadvertent ligation of superior mesenteric vessels

Laceration of retroperitoneal duodenum

Trauma to right ureter

Avulsion of branch between inferior pancreaticoduodenal and middle colic veins

Failure of anastomosis

OPERATIVE STRATEGY

The extent of the resection depends on the location of the tumor. For tumors of the cecum, the main trunk of the middle colic artery may be preserved (Fig. 2-1). For tumors of the hepatic flexure or right transverse colon, it is necessary to ligate this vessel and resect additional colon (Figs. 2-2, 2-3).

There are several anatomic advantages to the “no touch technique” described here, although the oncologic advantages are still debated. First, a dissection initiated at the origins of the middle colic and ileo-

colic vessels makes it possible to perform a more complete lymph node dissection in these two critical areas. Second, by devoting full attention to the lymphovascular pedicles early during the operation, before the anatomy has been distorted by traction or bleeding, the surgeon gains thorough knowledge of the anatomic variations that may occur in the vasculature of the colon. Finally, the surgeon becomes adept at performing the most dangerous step of this procedure—high ligation of the ileocolic vessels—without traumatizing the superior mesenteric artery and vein.

In most cases when the vascular pedicles are ligated close to their points of origin, it can be seen that the right colon is supplied by two vessels: the ileocolic trunk and the middle colic artery. The middle colic artery generally divides early in its course into right and left branches. The left branch forms a well developed marginal artery that connects with the left colic artery at the splenic flexure. When the proximal half of the transverse colon is removed, the left colic connection of this marginal artery supplies the remaining transverse colon. *Rarely*, a patient does not have good arterial flow from the divided marginal artery. In such a case the splenic flexure and sometimes the descending and sigmoid colon may have to be resected.

After the two major lymphovascular pedicles have been divided and ligated, the remainder of the mesentery to the right colon and the mesentery to the distal segment of the ileum should be divided. If occluding clamps are applied to the anticipated points of transection of the transverse colon and the ileum at this time, the entire specimen can be seen to be isolated from any vascular connection with the patient. This is all done before there is any manipulation of the tumor—hence the “no touch” technique. The specimen may now be removed by the traditional method of incising the peritoneum in the right paracolic gutter and elevating the right colon.

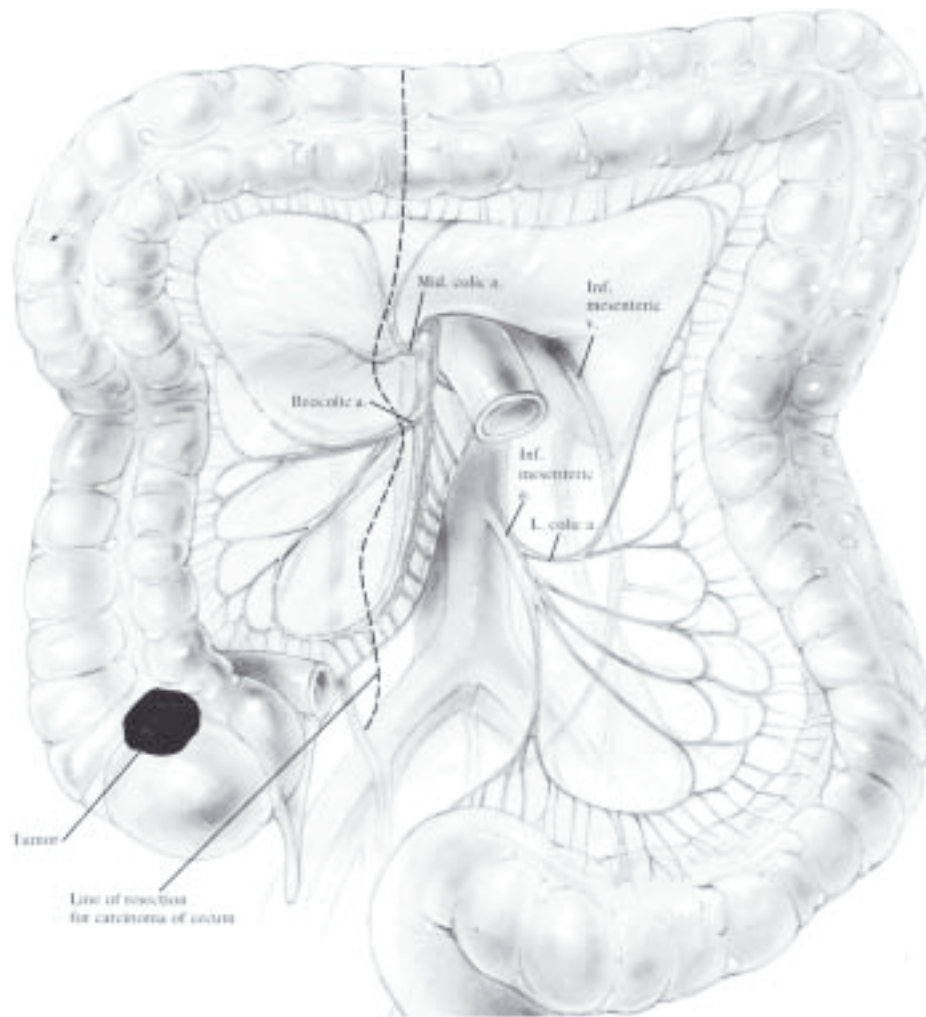


Fig. 2-1

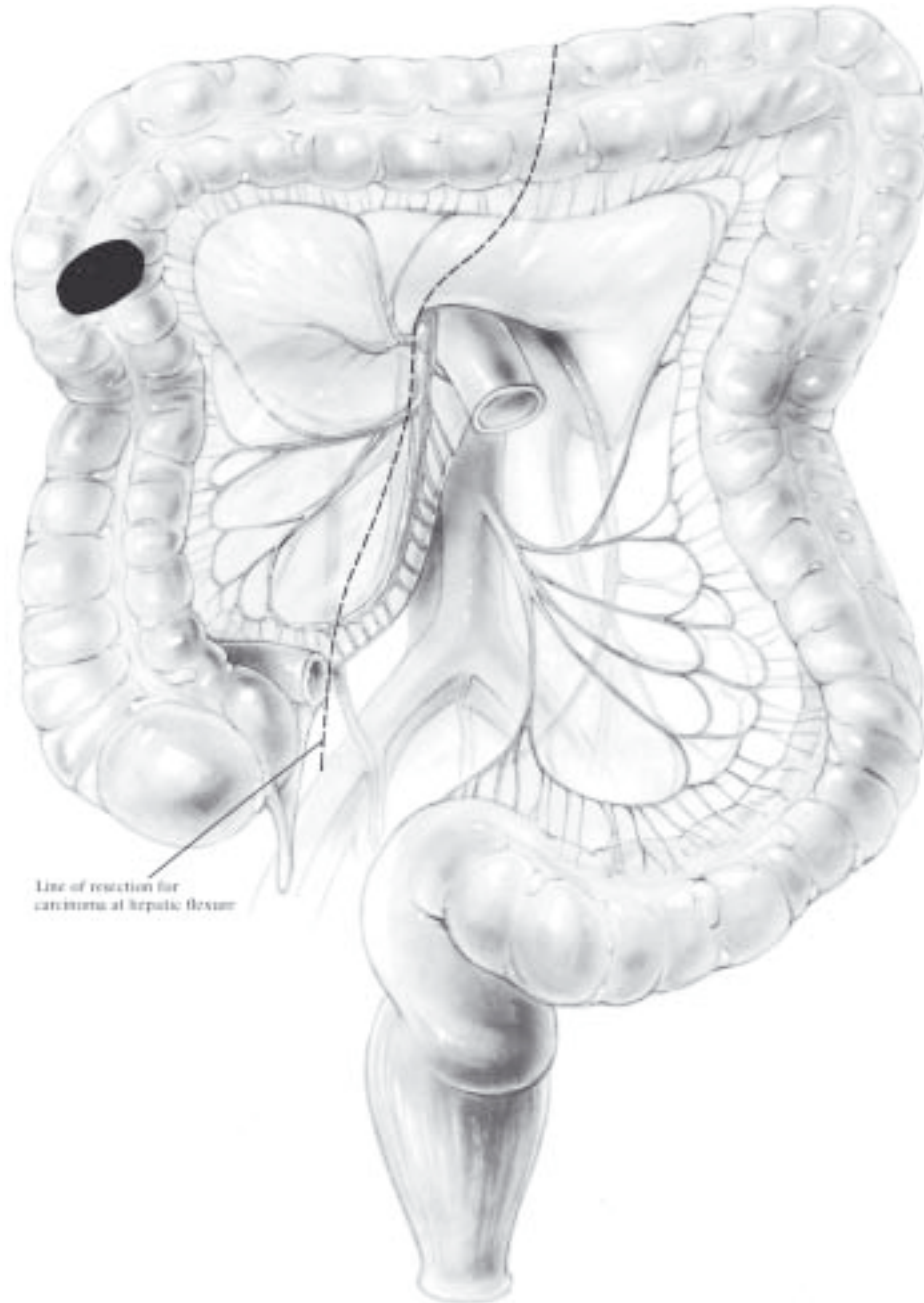


Fig. 2-2

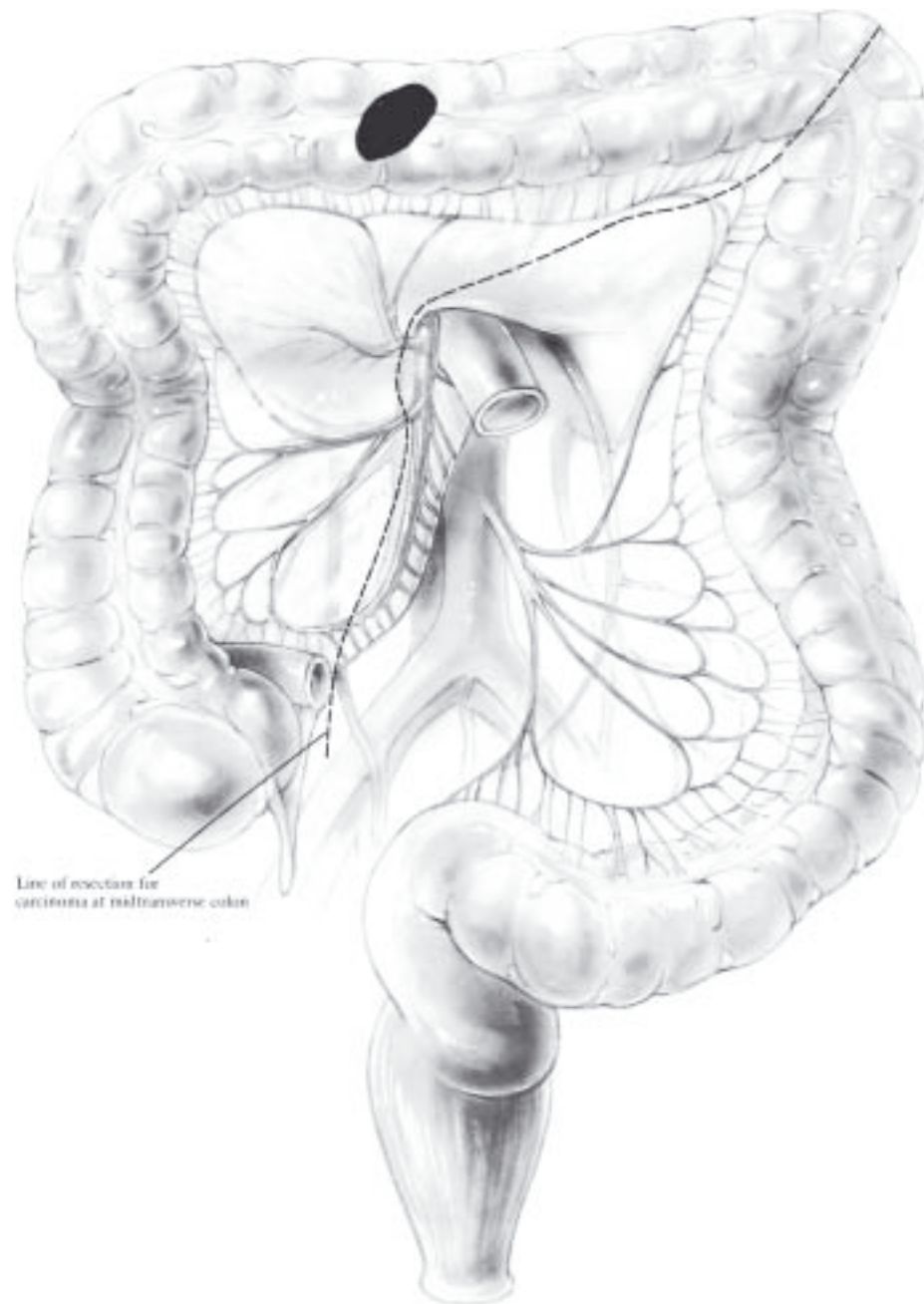


Fig. 2-3

OPERATIVE TECHNIQUE (Right and Transverse Colectomy)

Incision

Make a midline incision from the mid-epigastrium to a point about 8 cm below the umbilicus. Explore the abdomen for hepatic, pelvic, peritoneal, and nodal metastases. A solitary hepatic metastasis may well be resected at the same time the colectomy is performed. A moderate degree of hepatic metastasis is not a contraindication to removing a locally resectable colon carcinoma. Inspect the primary tumor but avoid manipulating it at this stage.

Ligature of Colon Proximal and Distal to Tumor

Insert a blunt Mixer right-angle clamp through an avascular portion of the mesentery close to the colon, distal to the tumor, and draw a 3 mm umbilical tape through this puncture in the mesentery. Tie the umbilical tape firmly to occlude the lumen of the colon completely. Carry out an identical maneuver at a point on the terminal ileum, thereby completely occluding the lumen proximal and distal to the tumor.

Omental Dissection

For a carcinoma located in the hepatic flexure, divide the adjacent omentum between serially applied Kelly hemostats just distal to the gastroepiploic arcade of the stomach (Fig. 2-4). If the neoplasm is located in the cecum, there appears to be no merit in resecting the omentum. The omentum may be dissected (with scalpel and Metzenbaum scissors) off the right half of the transverse colon through the avascular plane, resecting only portions adhering to the cecal tumor. After this has been accomplished, with the transverse colon drawn in a caudal direction the middle colic vessels can be seen as they emerge from the lower border of the pancreas to cross over the retroperitoneal duodenum.

Division of Middle Colic Vessels

During operations for carcinoma of the cecum and the proximal 5-7 cm of the ascending colon, it is not necessary to divide the middle colic vessels before they branch (Fig. 2-1). The left branch of the middle colic vessel may be preserved and the right branch divided and ligated just beyond the bifurcation (Fig. 2-5).

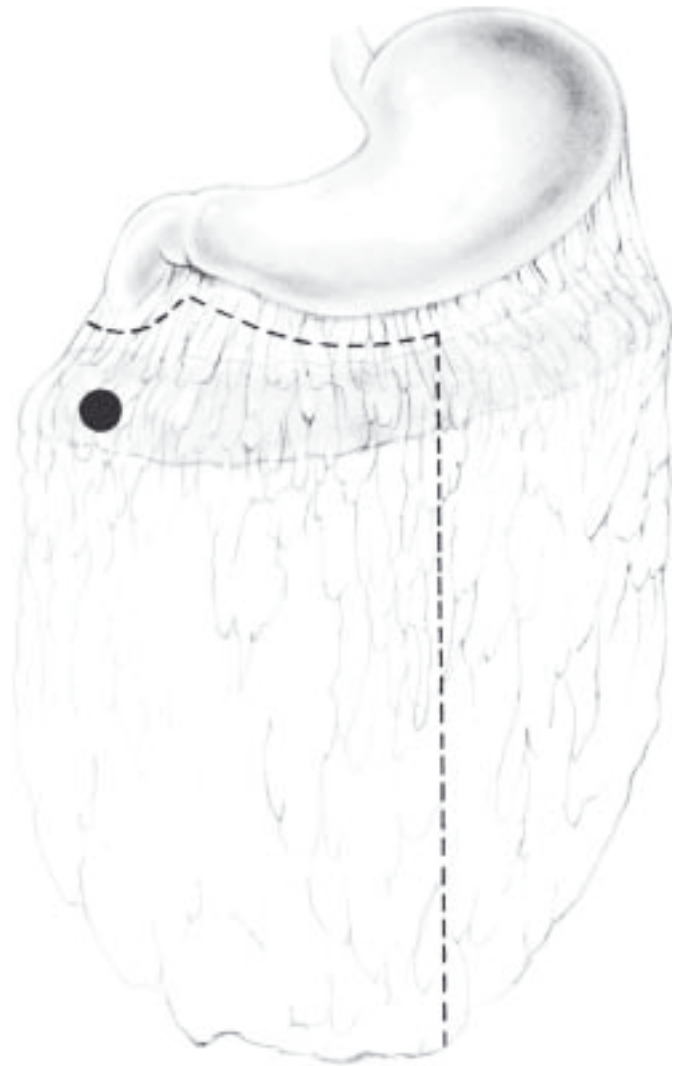

Fig. 2-4

During operations for tumors near the hepatic flexure of the transverse colon, dissect the middle colic vessels up to the lower border of the pancreas (Figs. 2-2, 2-3, 2-6). Be careful not to avulse a fairly large collateral branch that connects the inferior pancreaticoduodenal vein with the middle colic vein (Fig. 2-7). If this is torn, considerable bleeding follows, as the proximal end of the pancreaticoduodenal vein retracts and is difficult to locate. Gentle dissection is necessary, as these structures are fragile. Place a Mixer clamp deep to the middle colic vessels at the appropriate point; then draw a 2-0 silk ligature around the vessels and ligate them. Sweep any surrounding lymph nodes down toward the specimen and place a second ligature 1.5 cm distal to the first. Divide the vessels 1 cm beyond the proximal ligature.

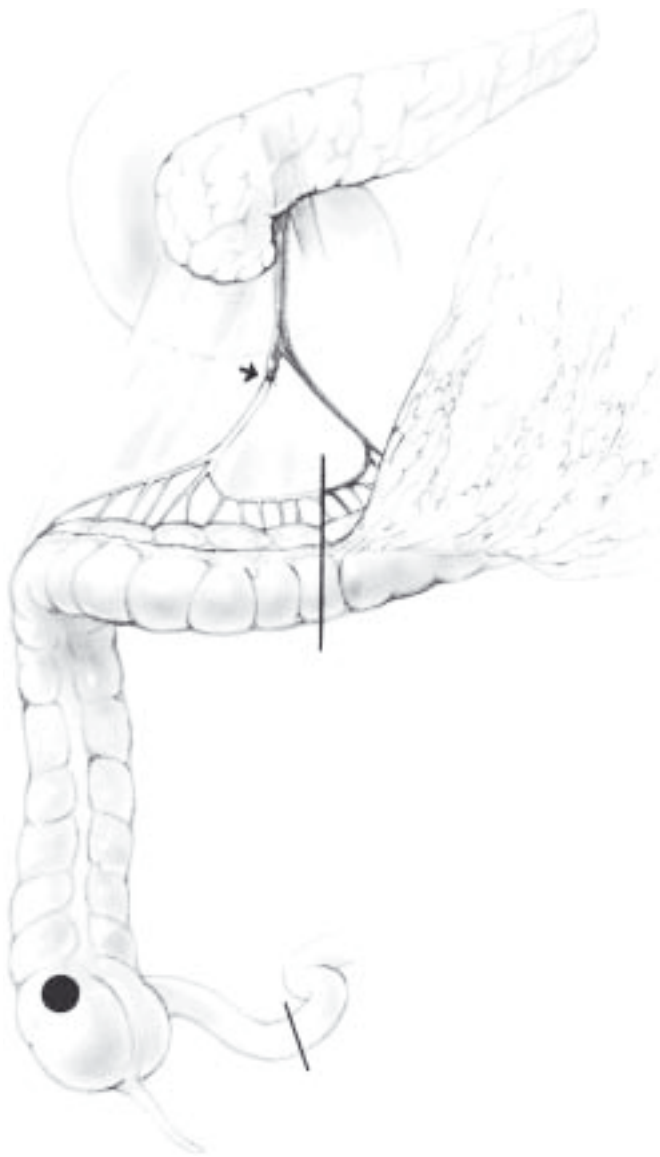

Fig. 2-5

Divide the mesocolon toward the point on the transverse colon already selected for division. Divide and ligate the marginal artery and clear the transverse colon of fat and areolar tissue in preparation for an anastomosis. Now apply an Allen clamp to the transverse colon, but to minimize bacterial contamination of the abdominal cavity do not transect the colon at this time.

Division of Ileocolic Vessels

Retract the transverse colon in a cephalad direction. Pass the left index finger deep to the right mesocolon

(Fig. 2-8) , inserting the finger through the incision already made in the transverse mesocolon. Gentle finger dissection should disclose, in front of the fingertip, a fairly large artery with vigorous pulsation; it is the ileocolic arterial trunk (Fig. 2-8). As the surgeon's index finger moves toward the patient's left, it palpates the adjacent superior mesenteric artery. After identifying these two major vessels, it is a simple matter to incise the peritoneum overlying the ileocolic artery with Metzenbaum scissors. By gentle dissection, remove areolar and lymphatic tissue from the circumference of the ileocolic artery and vein. After rechecking the location of the superior mesenteric vessels, pass a blunt Mixer right-angle clamp underneath the ileocolic artery and vein. Ligate the

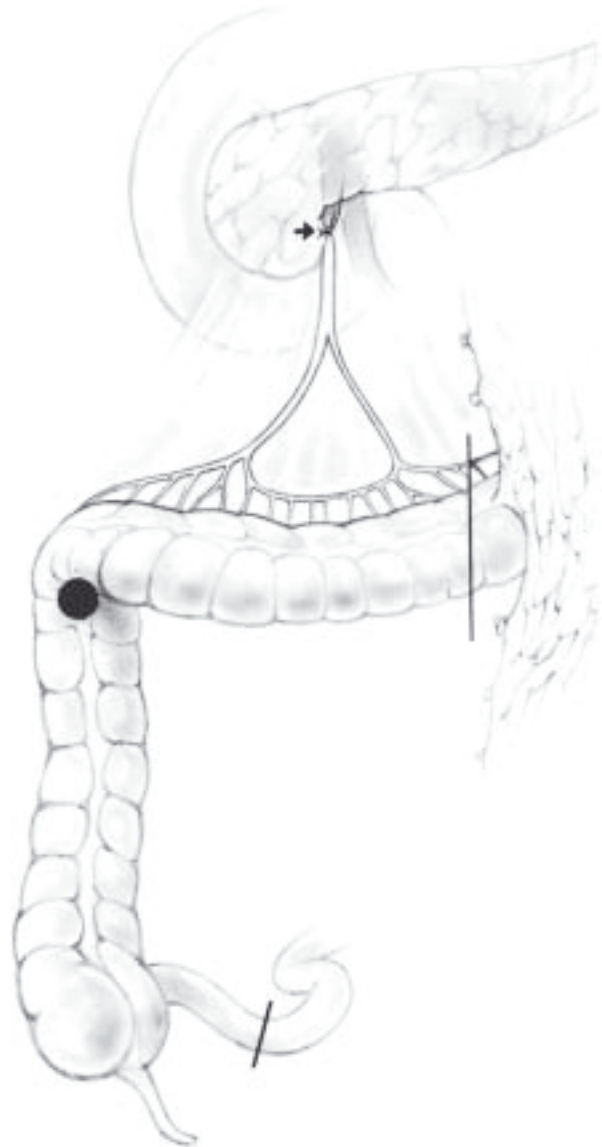


Fig. 2-6

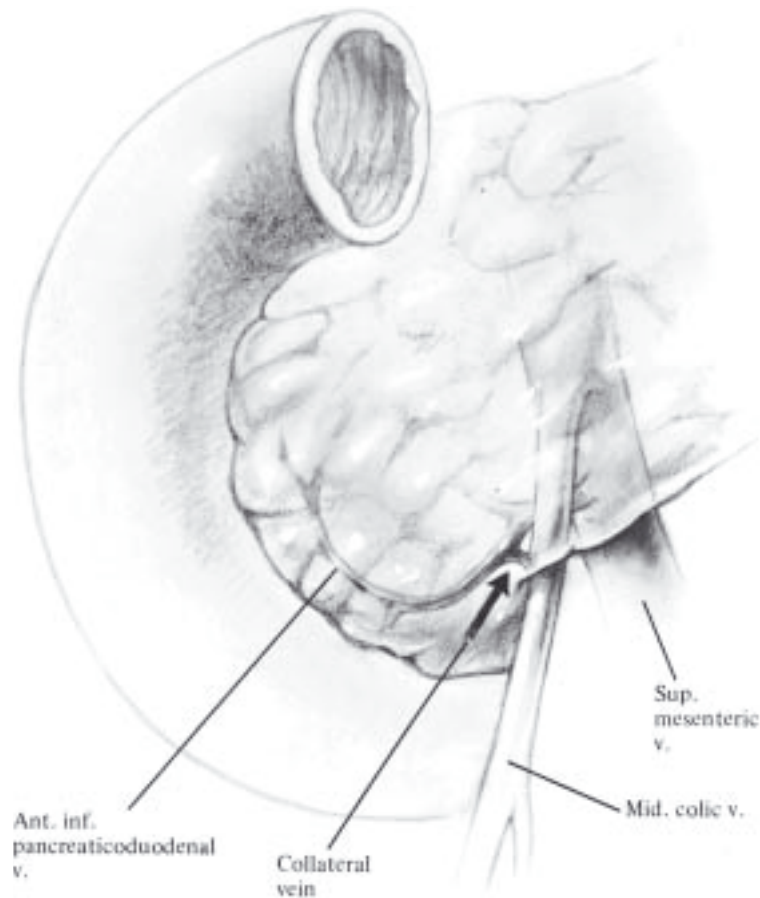


Fig. 2-7

vessels individually with 2-0 silk ligatures and divide them at a point about 1.5 cm distal to their junctions with the superior mesenteric vessels.

Division of Ileal Mesentery

Pass the left index finger behind the remaining right mesocolon into an avascular area of 3-4 cm. This can be divided and leads to the mesentery of the terminal ileum. For neoplasms close to the ileocecal junction, include 10-15 cm of ileum in the specimen.

For tumors near the hepatic flexure, no more than 8-10 cm of ileum need be resected. In any case, divide the ileal mesentery between Crile hemostats applied serially until the wall of the ileum has been encountered. After ligating each of the hemostats with 3-0 or 2-0 PG, clear the areolar tissue from the circumference of the ileum in preparation for an anastomosis and apply an Allen clamp to this area.

At this point the specimen has been isolated from any vascular connection with the host.

Division of Right Paracolic Peritoneum

Retract the right colon in a medial direction and make an incision in the peritoneum of the paracolic gutter (Fig. 2-8). The left index finger may be inserted deep to this layer of peritoneum, which should then be transected over the index finger with Metzenbaum scissors or electrocautery. Continue this dissection until the hepatic flexure is free of lateral attachments. Rough dissection around the retroperitoneal duodenum may lacerate it inadvertently, so be aware of its location. Next, identify the right renocolic ligament and divide it by Metzenbaum dissection. When this is accomplished, the fascia of Gerota and the perirenal fat may be gently swept from the posterior aspect of the right mesocolon. Continue

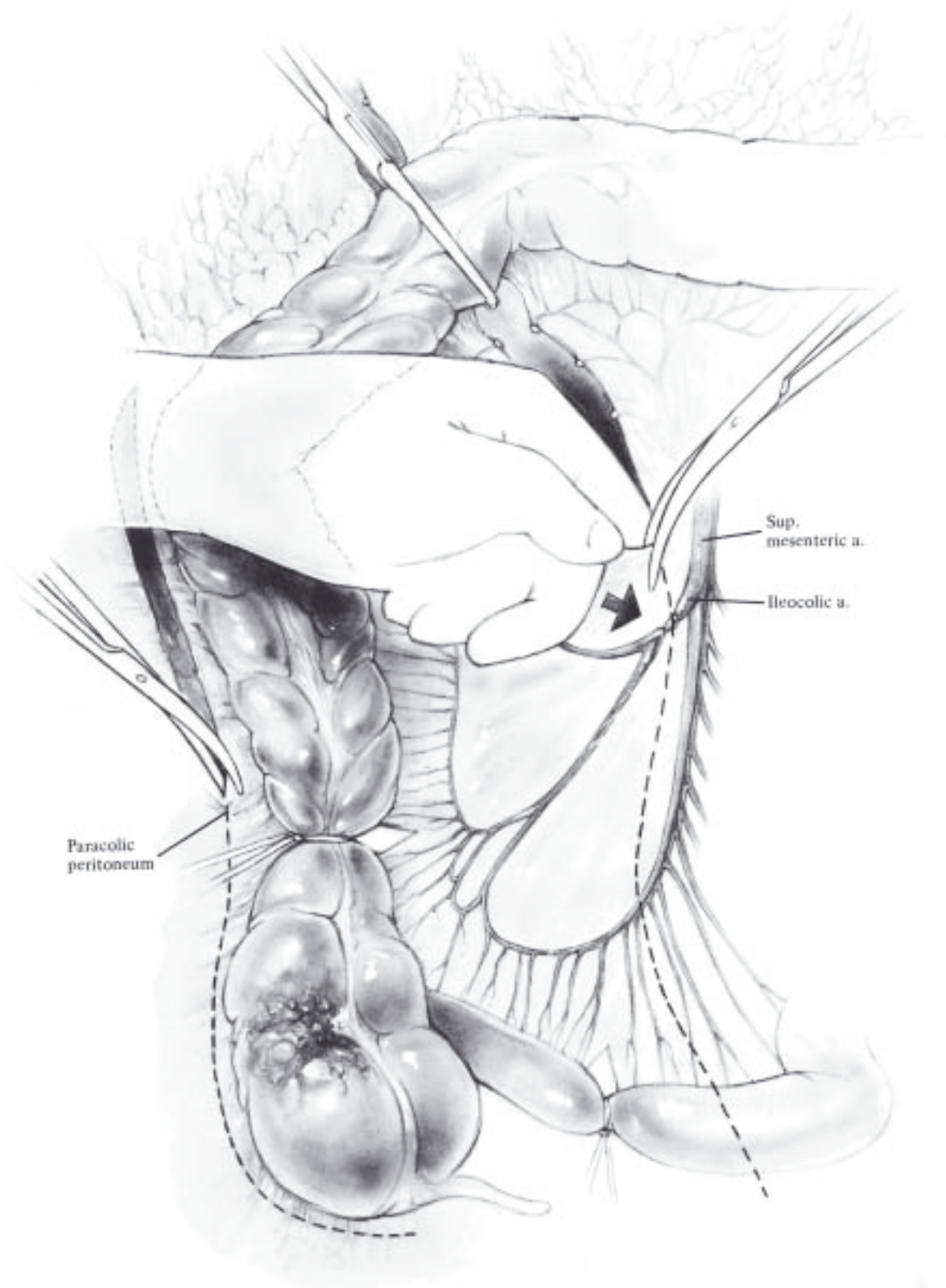


Fig. 2-8

this dissection caudally, eventually unroofing the ureter and gonadal vessel.

Identification of Ureter

If the location of the ureter is not immediately evident, identify the right common iliac artery. The undisturbed ureter generally crosses the common iliac artery where it bifurcates into its internal and external branches. If the ureter is not in this location, elevate the lateral leaflet of the peritoneum, as the ureter may be adhering to the undersurface of this peritoneal flap. The ureter is often displaced by retraction of the peritoneal flap to which it adheres. If the ureter is not present on the lateral leaflet of peritoneum, similarly elevate and seek it on the medial leaflet of the peritoneum. Typical ureteral peristalsis should occur when the ureter is compressed with forceps.

The right colon remains attached to the peritoneum now only at the inferior and medial aspects of the cecum and ileum. There should be no difficulty dividing it.

Division of Ileum and Colon

Protect the abdomen with large gauze pads and remove the specimen and the Allen clamps that had been applied to the ileum and transverse colon. If necessary, linen-shod Doyen noncrushing intestinal clamps may be applied to occlude the ileum and transverse colon at a point at least 10 cm from their cut edges in preparation for an open, two-layer end-to-end anastomosis (Fig. 2-9).

Before the anastomosis is begun, the blood supply must be carefully evaluated. Generally there is no problem with the terminal ileum if no hematoma has been induced. Test the adequacy of the blood supply to the cut end of the colon by palpating the pulse in the marginal artery. For additional data about the blood supply, divide a small arterial branch near the cut end of the colon and observe the pulsatile arterial flow. If there is any question about the vigor of the blood supply, resect additional transverse colon.

Ileocolic Two-Layer Sutured End-to-End Anastomosis

Align the cut ends of the ileum and transverse colon to face each other so their mesenteries are not twisted. Because the diameter of ileum is narrower than that of the colon, make a Cheatle slit with Metzzenbaum scissors on the antimesenteric border of the ileum for a distance of 1-2 cm to help equalize

these two diameters (Fig. 2-10). Do not round off the corners of the slit.

Insert the first seromuscular layer of interrupted sutures using 4-0 silk on atraumatic needles. Initiate this layer by inserting the first Lembert suture at the antimesenteric border and the second at the mesenteric border to serve as guy sutures. Attach hemostats to each of these sutures. Drawing the two hemostats apart makes insertion of additional sutures by successive bisection more efficient (Fig. 2-11). Now complete the anterior seromuscular layer of the anastomosis by inserting interrupted Lembert seromuscular sutures (Fig. 2-12). After the entire anterior layer has been inserted and tied, cut the tails of all the sutures except the two guy sutures.

To provide exposure for the mucosal layer, invert the anterior aspect of the anastomosis by passing the hemostat containing the antimesenteric guy suture (Fig. 2-13, A) through the rent in the mesentery deep to the ileocolonic anastomosis. Then draw the mesenteric guy suture (Fig. 2-13, B) in the opposite direction and expose the mucosa for application of the first layer of mucosal sutures (Fig. 2-14). Use 5-0 PG, double-armed, and begin the first suture at the midpoint (Fig. 2-15A). Then pass the suture in a continuous fashion toward the patient's right to lock each stitch. Take relatively small bites (4 mm). When the right margin of the suture line is reached, tag the needle with a hemostat; with the second needle initiate the remainder of the mucosal approximation, going from the midpoint of the anastomosis toward the patient's left in a continuous locked fashion (Fig. 2-15B). When this layer has been completed (Fig. 2-15C), close the superficial mucosal layer of the anastomosis with continuous Connell or Cushing sutures beginning at each end of the anastomosis. Terminate the mucosal suture line in the midpoint of the superficial layer by tying the suture to its mate (Fig. 2-16).

Accomplish the final seromuscular layer by inserting interrupted 4-0 silk Lembert sutures (Fig. 2-17). Devote special attention to ensuring a secure closure at the mesenteric border. Then cut all the sutures and test the lumen with thumb and forefinger to gauge the width of the anastomotic stoma. It should admit the tip of the thumb.

Close the defect in the mesentery by continuous 2-0 PG sutures. Take care to avoid occluding important vessels running in the mesentery during the course of the continuous suture. If desired, a one-layer anastomosis can be constructed by the technique described above, simply by omitting the mucosal suture. If it is accomplished without error, the result is as successful as after the two-layer method.

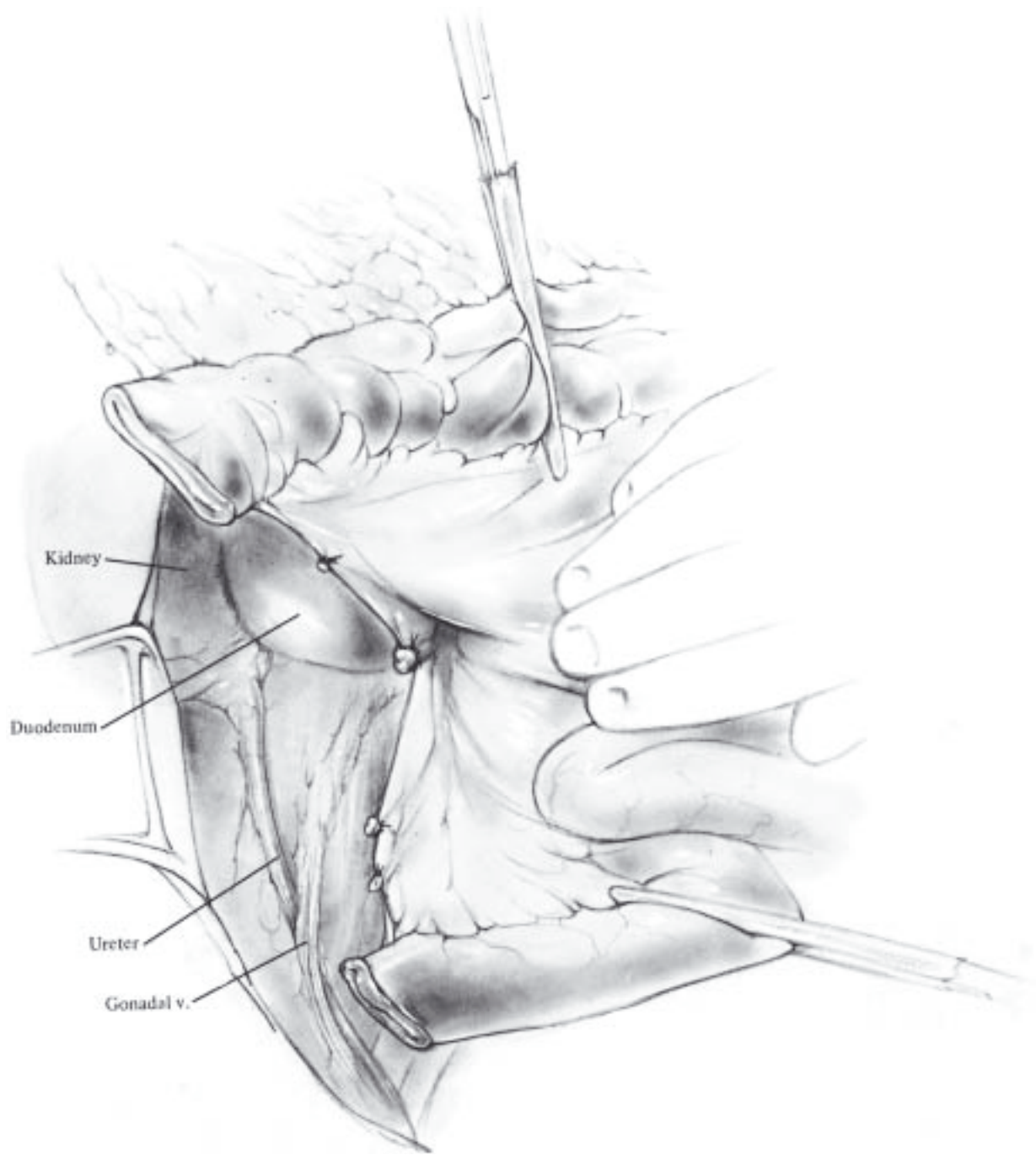


Fig. 2-9

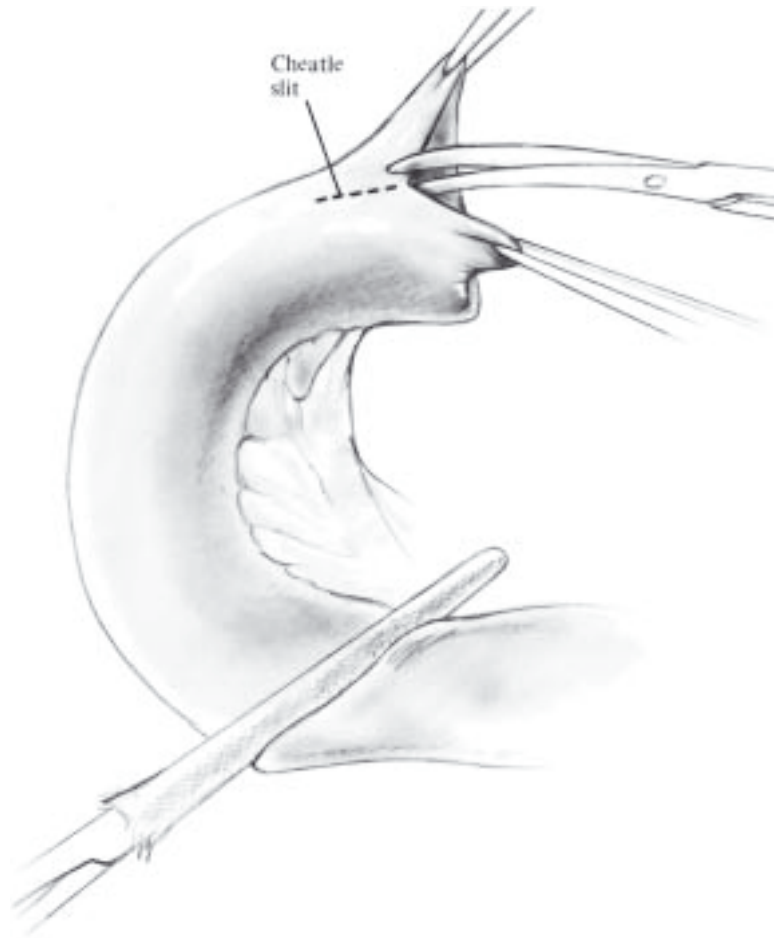


Fig. 2-10

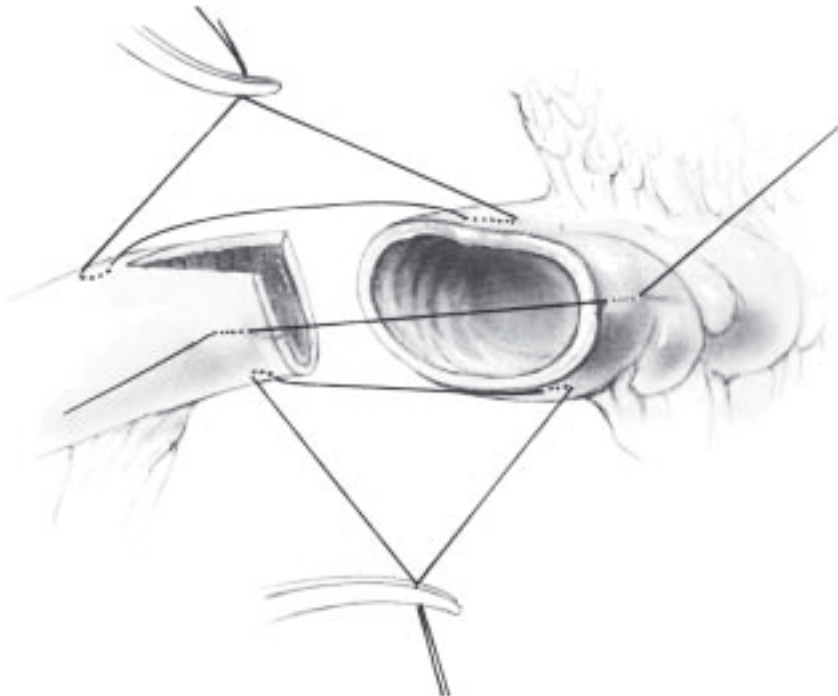


Fig. 2-11

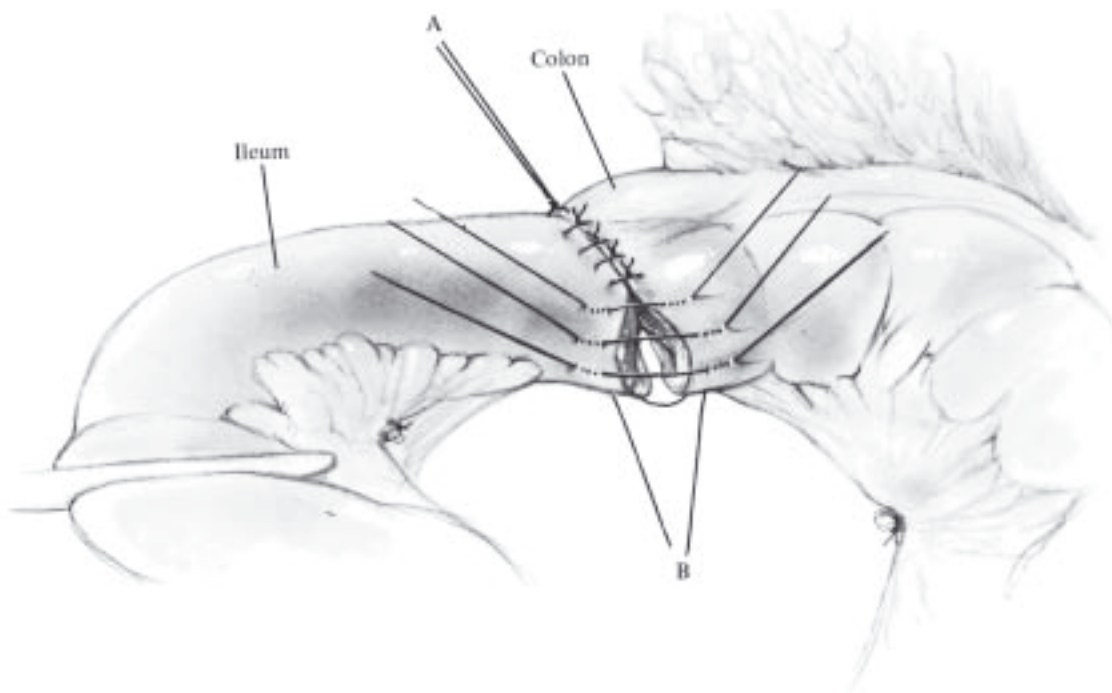


Fig. 2-12

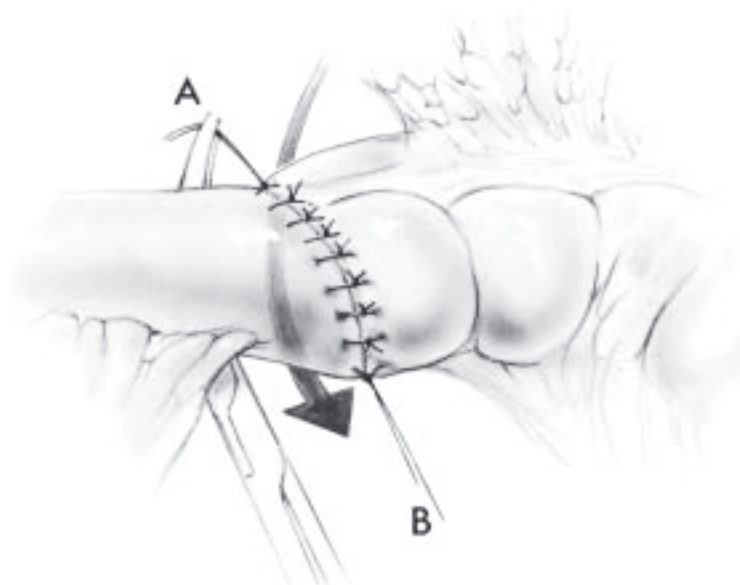


Fig. 2-13

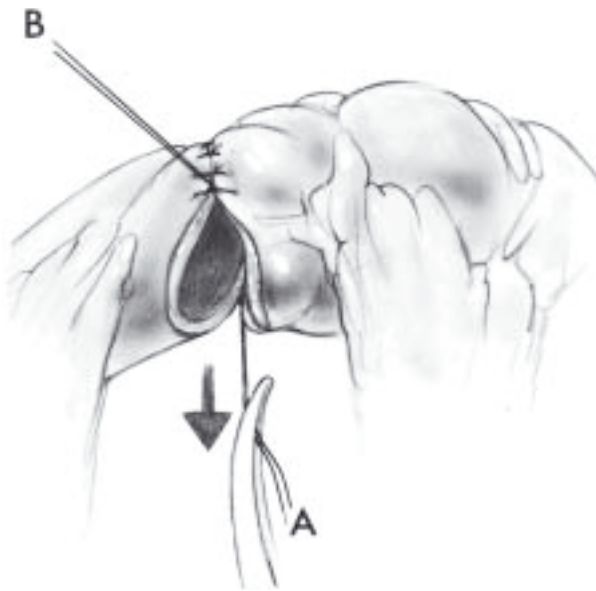


Fig. 2-14

Anastomosis by Stapling, Functional End-to-End

To perform a stapled anastomosis, clear an area of mesentery and apply the 55/3.5 mm linear stapler transversely across the colon. Transect the colon flush with the stapler using a scalpel. Carry out the identical procedure at the selected site on the ileum. Alternatively, the bowel may be stapled and divided with the linear cutting stapler. Some oozing of blood should be evident despite the double row of staples. Control excessive bleeding by carefully applying electrocoagulation or chromic sutures. Align the ileum and colon side by side and with heavy scissors excise a triangular 8 mm wedge from the antimesenteric margins of both ileum and colon (Fig. 2-18).

Insert one of the two forks of the cutting linear stapling instrument into the lumen of the ileum and the other into the colon, *bugging the antimesenteric border* of each (Fig. 2-19). Neither segment of intestine should be stretched, as it may result in excessive thinning of the bowel, leaving inadequate substance for the staples to grasp. After ascertaining that both segments of the bowel are near the hub of the stapler, fire the device; this should result in a side-to-side anastomosis 4-5 cm long. Unlock and remove the device and inspect the staple line for bleeding and possible technical failure when closing the staples.

Now apply Allis clamps to the remaining defect in the anastomosis and close it by a final application of the 55/3.5 mm linear stapling instrument (Fig. 2-20). Take care to include a portion of *each of the previously applied staple lines* in the final application of the stapler. However, when applying the Allis clamps, do not align points X and Y (Fig. 2-21) exactly opposite each other, as it would result in six staple lines meeting at one point. The alignment of these two points, as shown in Figure 2-22, produces the best results. Check the patency of the anastomosis by invaginating the colon through the anastomosis, which should admit the tips of two fingers. Then lightly touch the everted mucosa with the electrocautery instrument. During closure of the mesentery, cover the everted staple lines with adjoining mesentery or omentum if convenient.

We have modified Steichen's method of anastomosing ileum to colon, making it simpler by eliminating two applications of the stapler. With our technique the first step is to insert the cutting linear stapling device, one fork into the open end of ileum and the other fork into the open colon. Then fire the stapler, establishing a partial anastomosis between the antimesenteric borders of ileum and colon, as seen in Figure 2-21. Apply four or five Allis clamps to approximate the lips of the ileum and colon (in eversion) taking care that points X and Y are not in apposition. Then apply a 90/3.5 mm linear stapler underneath the Allis clamps and fire the staples. The end result is illustrated in Figure 2-23. In our experience this is the most efficient and reliable method for constructing an ileocolonic anastomosis.

Wound Closure

The surgical team now changes gloves and discards all instruments used up to this point. Irrigate the operative field with saline. Cover the anastomosis with omentum if possible. Close the abdomen in routine fashion without drainage.

POSTOPERATIVE CARE

Continue nasogastric suction for 1-3 days.

Delay oral intake of liquid and food until the fifth or sixth postoperative day.

If ileus persists, delay oral intake further and perform CT of the abdomen to exclude abscess, obstruction, or leak.

In the absence of preoperative intraabdominal sepsis, discontinue antibiotics after the operation.

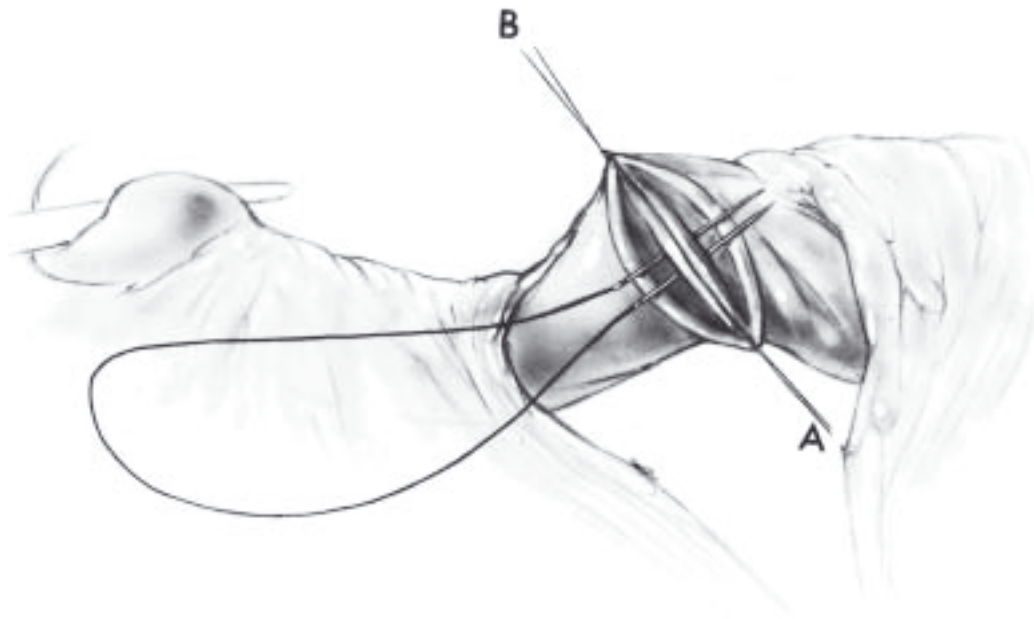


Fig. 2-15A

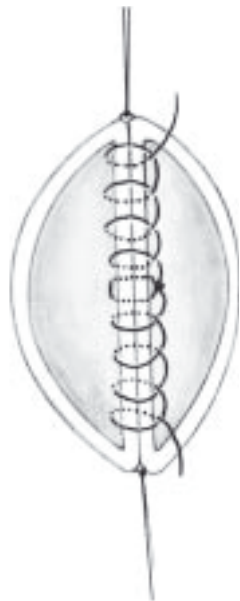

Fig. 2-15B

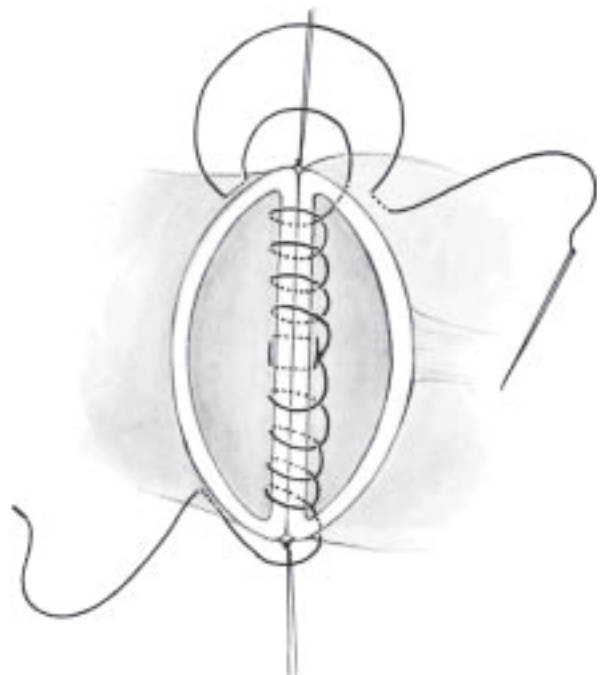


Fig. 2-15C

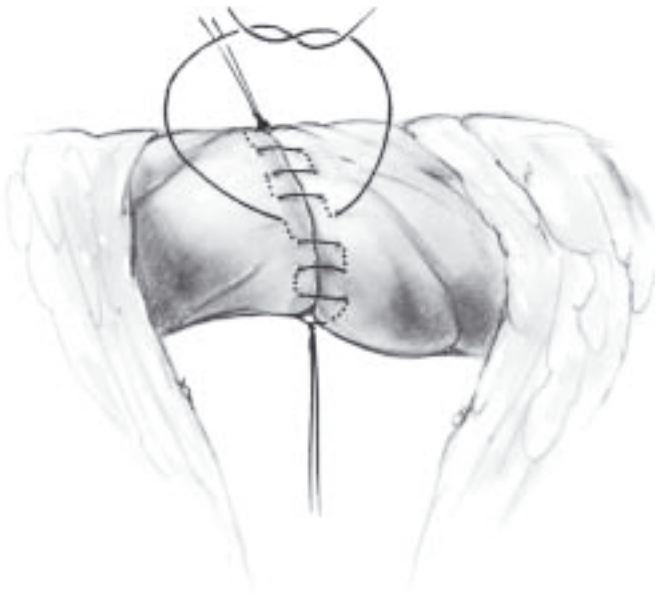

Fig. 2-16

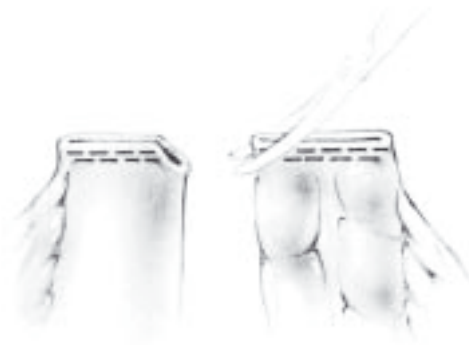

Fig. 2-18

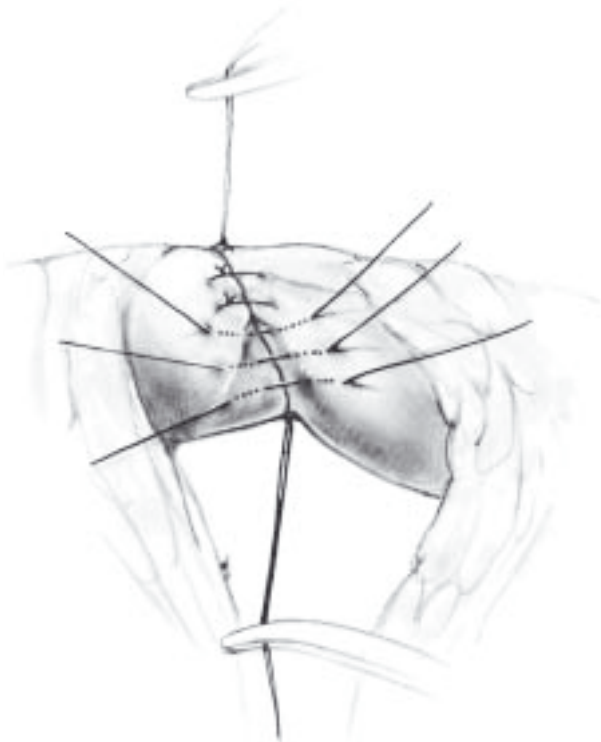


Fig. 2-17

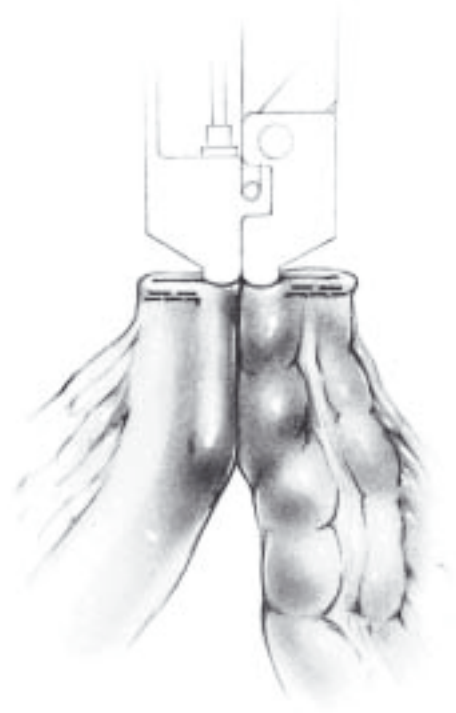


Fig. 2-19

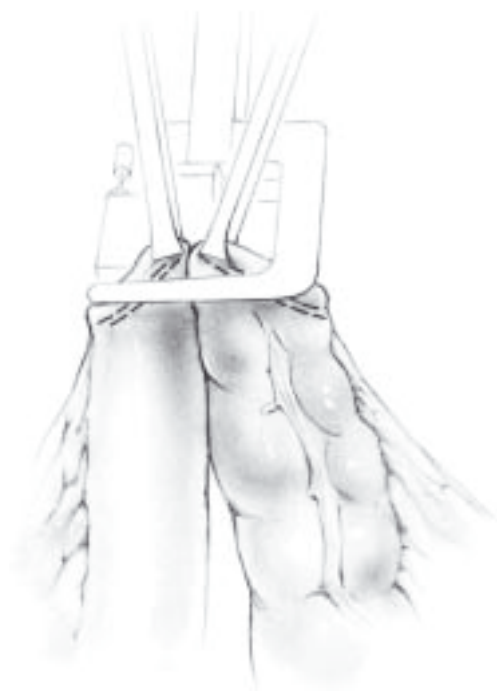

Fig. 2-20

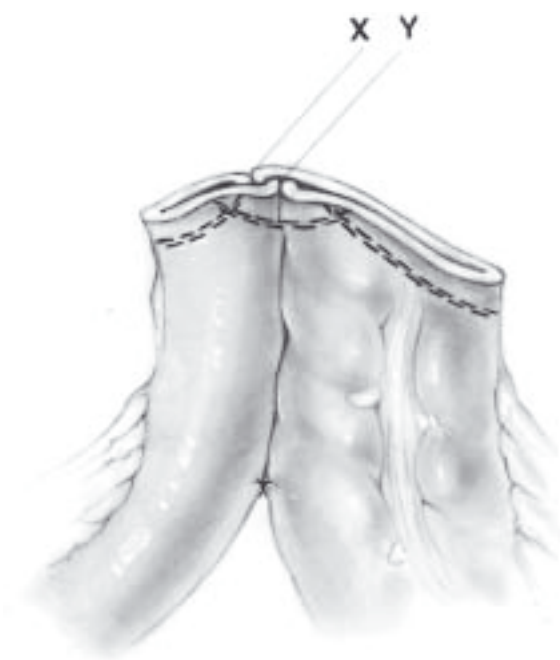

Fig. 2-22

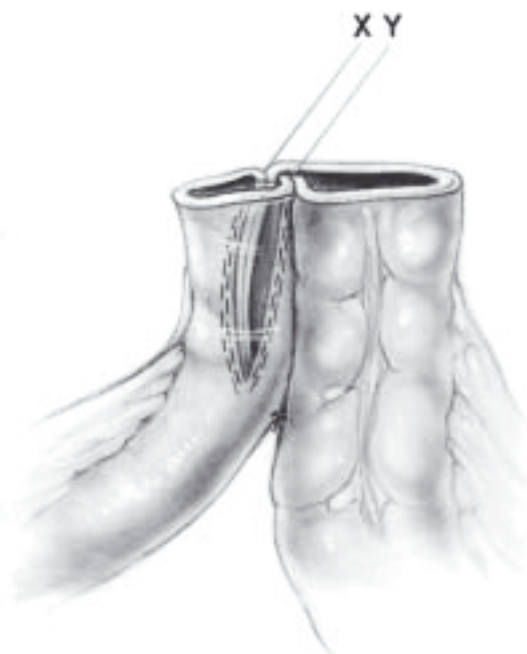

Fig. 2-21

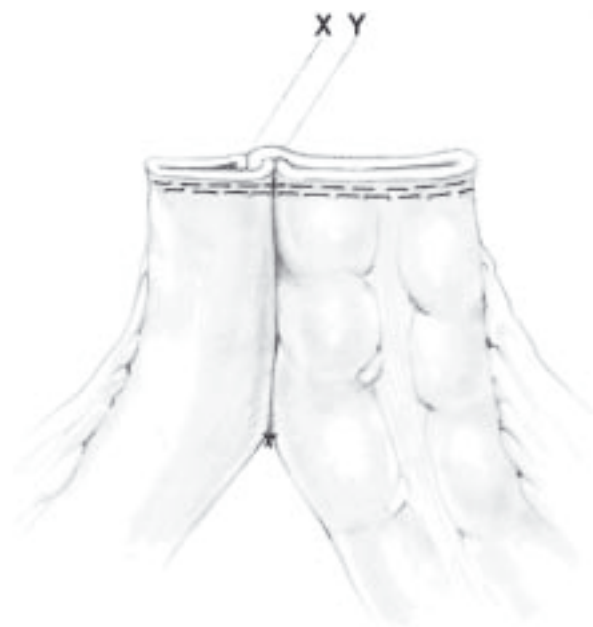

Fig. 2-23

COMPLICATIONS

Leakage from an ileocolonic or colocolonic anastomosis may manifest as peritonitis, colocutaneous fistula, or localized intraperitoneal abscess. Localized or spreading peritonitis should be managed by prompt relaparotomy and exteriorization of both ends of the anastomosis.

Sepsis in the subhepatic, subphrenic, or pelvic areas is an occasional complication of anastomoses of the colon, even in the absence of leakage. CT of the abdomen generally provides the diagnosis, and percutaneous drainage is usually successful.

Wound infection requires prompt removal of all overlying skin sutures to permit wide drainage of the entire infected area.

REFERENCES

- Furstenberg S, Goldman S, Machado M, Jarhult J. Minilaparotomy approach to tumors of the right colon. *Dis Colon Rectum* 1998;41:997.
- Heili MJ, Flowers SA, Fowler DL. Laparoscopic-assisted colectomy: a comparison of dissection techniques. *J Soc Laparoendosc Surg* 1999;3:27.
- Leung KL, Meng WC, Lee JP, et al. Laparoscopic-assisted resection of right-sided colonic carcinoma: a case-control study. *J Surg Oncol* 1999;71:97.
- Metcalf AM. Laparoscopic colectomy. *Surg Clin North Am* 2000;80:1321.
- Schirmer BD. Laparoscopic colon resection. *Surg Clin North Am* 1996;76:571.
- Young-Fadok TM, Nelson H. Laparoscopic right colectomy: five-step procedure. *Dis Colon Rectum* 2000; 2:267.
- Young-Fadok TM, Radice E, Nelson H, Harmsen WS. Benefits of laparoscopic-assisted colectomy for colon polyps: a case-matched series. *Mayo Clinic Proc* 2000; 75:344.