

# Eversion Carotid Endarterectomy

**R. Clement Darling III, Sean P. Roddy,  
Manish Mehta, Philip S.K. Paty,  
Kathleen J. Ozsvath, Paul B. Kreienberg,  
Benjamin B. Chang, Dhiraj M. Shah**

## INTRODUCTION

Several randomized trials have validated the use of carotid endarterectomy (CEA) for management of hemodynamically significant symptomatic and asymptomatic carotid artery stenosis (Executive Committee for the Asymptomatic Carotid Atherosclerosis Study 1995; North American Symptomatic Carotid Endarterectomy Trial Collaborators 1991). Classically, CEA has been accomplished through a longitudinal arteriotomy either primarily closed or with a patch comprising autogenous or prosthetic material (Hertzer et al. 1987).

The incidence of recurrent stenosis following standard longitudinal CEA ranges from 2% to 30% (Healy et al. 1989). Patch angioplasty closure requires either vein harvest or the use of a prosthetic, which may increase the incidence of bleeding and infection (Archie 1986; Hertzer et al. 1987; Lord et al. 1989). Furthermore, closure of a longitudinal carotid arteriotomy, even with patch, may not reduce restenosis of the distal internal carotid artery (ICA), where it is most narrow. In order to successfully negotiate these technical hurdles and minimize restenosis, occlusion, and stroke, some surgeons have turned to the alternative technique of eversion CEA (Darling et al. 2000; DeBakey et al. 1959; Kasparzak and Raithel 1989).

Eversion CEA has a history almost as old as CEA itself. A report by DeBakey et al. in 1959 illustrated the use of an everting technique in which the distal common carotid artery (CCA) was transected and the atheroma removed by everting the bifurcation while the internal and external carotid arteries remained attached (DeBakey et al. 1959). Both branches were left connected, with limited cephalad plaque exposure and visualization of the distal end point. Hence, this technique was considered unreliable in patients whose disease extended beyond the bifurcation, and the eversion technique never gained acceptance. For many years, the most effective application of the eversion endarterectomy technique involved its use in the external iliac and common femoral arteries, where surgeons were able to visualize the end points and perform autogenous arterial reconstructions with excellent results (Darling et al. 1993).

Separately, Berguer et al., and Kasparzak and Raithel in 1989, revised the DeBakey eversion CEA technique by transecting the ICA at the carotid bulb and reported their results of decreased recurrent stenosis and occlusion (Kasparzak and Raithel 1989). The primary advan-

tage of eversion CEA is that the ICA is divided at the largest part of the two vessels, and the subsequent anastomosis onto the CCA is easier with less potential for a closure related restenosis (Darling et al. 2000). This avoids a distal ICA suture line where the artery is narrow and its closure is prone to restenosis. Furthermore, the improved visualization facilitates plaque extraction, and management of the end points. These two seemingly small advantages in experienced hands result in reduced carotid cross-clamp time, total operative time, the incidence of carotid restenosis, and stroke mortality rates.

The technique of standard CEA has been performed with excellent results over the past 3 decades. Most surgeons are reluctant to change but there is always room for improvement. The eversion CEA technique offers just that by displacing the anastomosis from a narrow distal ICA to a larger carotid bulb and proximal ICA.

Surgeons adopting eversion CEA need not change the majority of their technique. The anesthetic choice as well as methods of cerebral monitoring and protection can be the same for both eversion and standard longitudinal CEA. We prefer eversion CEA under cervical block anesthesia, with selective shunting only in patients who develop neurological deterioration during cross-clamping (Chang et al. 2000).

As currently conceived, eversion CEA can be used to treat almost all cases of primary carotid bifurcation disease and selective cases of recurrent stenosis. This technique is ideal for treatment of carotid arteries with kinks or loops, as shortening of the ICA can be incorporated within the process of eversion.

The extent of disease at the bifurcation may affect one's ease in performing CEA by any method. Disease limited to or near the bifurcation is much easier to treat than disease that extends distally into the ICA. External visualization is used to adequately evaluate the distal extension of the atherosclerotic plaque prior to division of the ICA. Transition from a yellow atheromatous abnormal plaque to a smooth purplish pliable normal distal ICA usually signifies the type of disease that is easily correctable via eversion endarterectomy. Treatment of extensive disease in the ICA up to or beyond the level of the digastric muscle can be more difficult: such cases should be reserved until ample experience with eversion CEA is gained.

### Figure 1

Exposure of the carotid artery is identical with either method of endarterectomy. Although circumferential dissection of the ICA along its length is a necessary part of the eversion technique, this is best managed after clamping and division of the ICA. Thus, only sufficient dissection to accommodate the clamps need be performed initially. Following carotid artery exposure, the ICA should be externally examined. The plaque end point is visualized as the transition from the yellowish diseased artery to the normal bluish artery. Ideally the clamp should be placed across the normal artery well above the transition zone as this makes eversion of the ICA and examination of the end point easier. When the plaque extends cephalad to what is attainable by the usual measures of division of the ansa cervicalis, mobilization of the

hypoglossal nerve and division of the digastric muscle, an endarterectomy is difficult by any technique. In such cases, the operator should use whatever method is more familiar. The patient is systemically anticoagulated (30 u/kg body weight of intravenous heparin) and the carotid arteries are clamped. The ICA is obliquely divided at the carotid bulb. The line of transection should be in the range of 30–60 degrees from the horizontal and extend on to the CCA, encompassing most of the plaque. It is important for the line of transection to end in the crotch of the carotid bulb and not higher up into the internal or external carotids; failure to do so is not necessarily catastrophic but can increase the complexity of the anastomosis.

### Figure 2

After division, cephalad and lateral traction on the ICA helps with circumferential mobilization. This consists of the carotid sinus tissue medially and the looser areolar tissue posteriorly, in which the vagus nerve usually resides. Dissection close to and along the divided ICA mobilizes the remaining length of artery while avoiding injury to the adjacent structures.

Once freed from the surrounding tissue, some ICA redundancy is generally recognized in relation to the CCA. This redundancy may range from a very few millimeters to several centimeters in cases presenting with carotid kinks or loops. The heel of the ICA (side formerly adherent to the carotid body) is divided longitudinally such that it lines up with the upper end of the common carotid arteriotomy. The anterolateral border of the CCA is extended proximally to match the length of internal carotid arteri-

otomy. The resultant opening of the carotid arteries is usually 15–30 mm in length; this is important as the extra length allows a wider anastomosis which is easily performed with a lower chance of restenosis. Patients with extensively redundant ICAs require oblique *resection of a segment of ICA* excision of the ICA to match the common carotid arteriotomy. When CCA plaque cannot be adequately removed by eversion, the arteriotomy should be extended proximally to facilitate complete endarterectomy. Closure of the additional common carotid arteriotomy may be accomplished by “pulling down” the ICA and using it as a patch over the common carotid arteriotomy. Alternatively, the proximal common carotid arteriotomy may be closed primarily. The latter results in a Y-shaped suture line where the linear common carotid closure meets the circumferential CCA–ICA suture line.

Figure 1

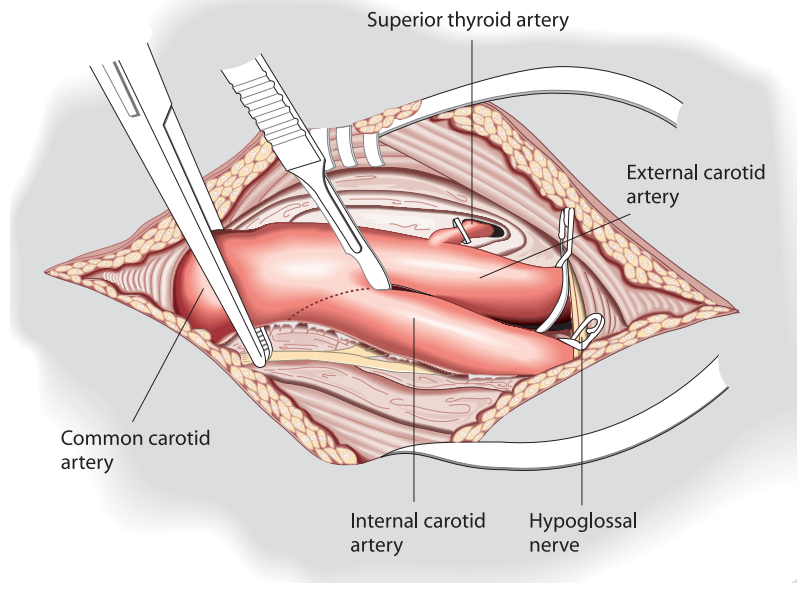


Figure 2

