

Anatomy, Function, and Evaluation of the Salivary Glands

F. Christopher Holsinger and Dana T. Bui

Contents

Introduction	2	Physiology of Salivary Glands	11
Developmental Anatomy	2	Evaluation of the Salivary Glands	13
Parotid Gland	2	History	13
Anatomy	2	Physical Examination	13
Fascia	3	Radiologic and Endoscopic Examination	
Stensen's Duct	3	of the Salivary Glands	14
Neural Anatomy	4		
Autonomic Nerve Innervation	4		
Arterial Supply	5		
Venous Drainage	6		
Lymphatic Drainage	6		
Parapharyngeal Space	6		
Submandibular Gland	6		
Anatomy	6		
Fascia	6		
Wharton's Duct	7		
Neural Anatomy	7		
Arterial Supply	8		
Venous Drainage	8		
Lymphatic Drainage	8		
Sublingual Gland	8		
Minor Salivary Glands	9		
Histology	9		

Core Features

- Embryology of the salivary glands and their associated structures
- Detailed anatomy of the parotid, submandibular, sublingual, and minor salivary glands, including nervous innervation, arterial supply, and venous and lymphatic drainage
- Histology and organization of the acini and duct systems within the salivary glands
- Physiology and function of the glands with respect to the production of saliva
- Considerations when taking a patient's history
- The intra- and extraoral aspects of inspection and palpation during a physical examination

Introduction

The human salivary gland system can be divided into two distinct exocrine groups. The *major salivary glands* include the paired parotid, submandibular, and sublingual glands. Additionally, the mucosa of the upper aerodigestive tract is lined by hundreds of small, *minor salivary glands*. The major function of the salivary glands is to secrete saliva, which plays a significant role in lubrication, digestion, immunity, and the overall maintenance of homeostasis within the human body.

Developmental Anatomy

In the last 15 years, significant improvement has been made in our understanding of the molecular basis of salivary gland development, supplanting and expanding classical teaching in the embryology and developmental anatomy.

Early work suggests that development of the salivary glands begins during the sixth to eighth embryonic week when oral ectodermal outpouchings extend into the adjacent mesoderm and serve as the site of origin for major salivary gland growth. The development of major salivary glands is thought to consist of three main stages [1, 8]. The first stage is marked by the presence of a primordial anlage (from the German verb *anlag*en, meaning to lay a foundation or to prepare) and the formation of branched duct buds due to repeated epithelial cleft and bud development. Ciliated epithelial cells form the lining of the lumina, while external surfaces are lined by ectodermal myoepithelial cells [2]. The early appearance of lobules and duct canalization occur during the second stage. Primitive acini and distal duct regions, both containing myoepithelial cells, form within the seventh month of embryonic life. The third stage is marked by maturation of the acini and intercalated ducts, as well as the diminishing prominence of interstitial connective tissue.

The first of the glands to appear, during the sixth gestational week, is the primordial *parotid gland*. It develops from the posterior stomodeum, which laterally elongates into solid cords across the developing masseter muscle. The cords then canalize to form ducts, and acini are formed at the distal ends. A capsule formed from the ambient mesenchyme surrounds the gland and associated lymph nodes [14]. Small buds appear in the floor of the mouth lateral to the tongue during the sixth week of embryonic

life and extend posteriorly around the mylohyoid muscle into the submandibular triangle. These buds eventually develop into the *submandibular glands*. A capsule from the surrounding mesenchyme is fully developed around the gland by the third gestational month [8]. During the ninth embryonic month, the *sublingual gland* anlage is formed from multiple endodermal epithelial buds in the paralingual sulcus of the floor of the mouth. Absence of a capsule is due to infiltration of the glands by sublingual connective tissue. Intraglandular lymph nodes and major ducts also do not generally develop within sublingual glands. Upper respiratory ectoderm gives rise to simple tubuloacinar units. They develop into the *minor salivary glands* during the 12th intrauterine week [17].

Recent work using murine models has shown the complexity of the underlying molecular events orchestrating classical embryological findings. Development of the salivary glands is an example of branching morphogenesis, a process fundamental to many developing organs, including lung, mammary gland, pancreas, and kidney [12]. Branching organs develop a complex arborization and morphology through a program of repetitive, self-similar branching forks to create new epithelial outgrowths. The developmental growth of a multicellular organ such as a salivary gland is based on a set of interdependent mechanisms and signaling pathways. The resulting expression of these pathways is dynamic, organized, and changes correspondingly with each developmental stage. The sonic hedgehog (Shh) signaling plays an essential role during craniofacial development [13]. Other pathways, including the fibroblast growth factor family of receptors and associated ligands, have also been shown to play a crucial role [28].

Parotid Gland

Anatomy

The paired parotid glands are the largest of the major salivary glands and weigh, on average, 15–30 g. Located in the preauricular region and along the posterior surface of the mandible, each parotid gland is divided by the facial nerve into a superficial lobe and a deep lobe (Fig. 1.1). The *superficial lobe*, overlying the lateral surface of the masseter, is defined as the part of the gland lateral to the facial nerve. The *deep lobe* is medial to the facial nerve and located between the mastoid process of the temporal




Fig. 1.1: The parotid gland and the facial nerve branching

bone and the ramus of the mandible. Most benign neoplasms are found within the superficial lobe and can be removed by a superficial parotidectomy. Tumors arising in the deep lobe of the parotid gland can grow and extend laterally, displacing the overlying superficial lobe without direct involvement. These parapharyngeal tumors can grow into “dumbbell-shaped” tumors, because their growth is directed through the stylomandibular tunnel [5].

The parotid gland is bounded superiorly by the zygomatic arch. Inferiorly, the tail of the parotid gland extends down and abuts the anteromedial margin of the sternocleidomastoid muscle. This tail of the parotid gland extends posteriorly over the superior border of the sternocleidomastoid muscle toward the mastoid tip. The deep lobe of the parotid lies within the parapharyngeal space [10].

An *accessory parotid gland* may also be present lying anteriorly over the masseter muscle between the parotid duct and zygoma. Its ducts empty directly into the parotid duct through one tributary. Accessory glandular tissue is histologically distinct from parotid tissue in that it may contain mucinous acinar cells in addition to the serous acinar cells [6].

Fascia

The deep cervical fascia continues superiorly to form the parotid fascia, which is split into superficial and deep layers to enclose the parotid gland. The thicker superficial fascia is extended superiorly from the masseter and sternocleidomastoid muscles to the zygomatic arch. The deep layer extends to the *stylomandibular ligament (or membrane)*, which separates the superficial and deep lobes of the parotid gland. The stylomandibular ligament is an important surgical landmark when considering the resection of deep lobe tumors. In fact, stylomandibular tenotomy [22] can be a crucial maneuver in providing exposure for en bloc resections of deep-lobe parotid or other parapharyngeal space tumors. The parotid fascia forms a dense inelastic capsule and, because it also covers the masseter muscle deeply, can sometimes be referred to as the *parotid masseteric fascia*.

Stensen's Duct

The parotid duct, also known as Stensen's duct, secretes a serous saliva into the vestibule of the oral cavity. From

1 the anterior border of the gland, it travels parallel to the zygoma, approximately 1 cm below it, in an anterior direction across the masseter muscle. It then turns sharply to pierce the buccinator muscle and enters the oral cavity opposite the second upper molar tooth.

Neural Anatomy

The facial nerve (CN VII) exits the skull base via the stylomastoid foramen, which is slightly posterolateral to the styloid process and anteromedial to the mastoid process. Before entering the posterior portion of the parotid gland, three motor branches are given off to innervate the posterior belly of the digastric muscle, the stylohyoid muscle, and the postauricular muscles.

The main trunk of the facial nerve then passes through the parotid gland and, at the *pes anserinus* (Latin: goose's foot), divides into the temporofacial and lower cervicofacial divisions approximately 1.3 cm from the stylomastoid foramen. The upper *temporofacial division* forms the frontal, temporal, zygomatic, and buccal branches. The lower *cervicofacial division* forms the marginal mandibular and cervical branches. Branches from the major upper and lower branches often anastomose to create the diverse network of midfacial buccal branches.

The *temporal branch* traverses parallel to the superficial temporal vessels across the zygoma to supply the frontal belly of the occipitofrontalis muscle, the orbicularis oculi, the corrugator supercilii, and the anterior and superior auricular muscles. The *zygomatic branch* travels directly over the periosteum of the zygomatic arch to innervate the zygomatic, orbital, and infraorbital muscles. The *buccal branch* travels with Stensen's duct anteriorly over the masseter muscle to supply the buccinator, upper lip, and nostril muscles. Buccal branches can either arise from the upper temporofacial or the lower cervicofacial division. The *marginal mandibular branch* courses along the inferior border of the parotid gland to innervate the lower lip and chin muscles. It lies superficial to the posterior facial vein and retromandibular veins in the plane of the deep cervical fascia directly beneath the platysma muscle. The *cervical branch* supplies the platysma muscle. Like the marginal mandibular branch, it is located within the plane of the deep cervical fascia direct underneath the platysma.

Small connections can exist among the temporal, zygomatic, and buccal branches, and anatomic variations in facial nerve branching patterns occur commonly. Each

terminal branch can be located distally and traced retrograde across the parotid gland to the main trunk of the facial nerve. The facial nerve can also be identified at the stylomastoid foramen by performing a mastoidectomy if identification by the usual landmarks is not possible [5, 10, 23].

The great auricular nerve is a sensory branch of the cervical plexus, particularly C2 and C3, and innervates the posterior portion of the pinna and the lobule. The nerve parallels the external jugular vein along the lateral surface of the sternocleidomastoid muscle to the tail of the parotid gland, where it splits into anterior and posterior branches. The great auricular nerve is often injured during parotidectomy, which can result in long-term sensory loss in the lobule. Harvesting of this nerve can be used for facial nerve grafting in certain cases.

The auriculotemporal nerve is a branch of the mandibular nerve, the third inferior subdivision of the trigeminal nerve (V₃). After exiting the foramen ovale, the nerve traverses superiorly to innervate the skin and scalp immediately anterior to the ear. Its course runs parallel to the superficial temporal vessels and anterior to the external auditory canal.

Autonomic Nerve Innervation

The glossopharyngeal nerve (CN IX) provides visceral secretory innervation to the parotid gland. The nerve carries preganglionic parasympathetic fibers from the inferior salivatory nucleus in the medulla through the jugular foramen (Fig. 1.2). Distal to the inferior ganglion, a small branch of CN IX (*Jacobson's nerve*) reenters the skull through the inferior tympanic canaliculus and into the middle ear to form the *tympanic plexus*. The preganglionic fibers then course along as the lesser petrosal nerve into the middle cranial fossa and out the foramen ovale to synapse in the *otic ganglion*. Postganglionic parasympathetic fibers exit the otic ganglion beneath the mandibular nerve to join the auriculotemporal nerve in the infratemporal fossa. These fibers innervate the parotid gland for the secretion of saliva. Postganglionic sympathetic fibers innervate salivary glands, sweat glands, and cutaneous blood vessels through the external carotid plexus from the *superior cervical ganglion*. Acetylcholine serves as the neurotransmitter for both postganglionic sympathetic and parasympathetic fibers [10]. This physiologic coincidence allows for the development of "gustatory sweating" (also known as Frey's syndrome)




Fig. 1.2: Parasympathetic supply to the major salivary glands

following parotidectomy [19, 26]. Patients develop sweating and flushing of the skin overlying the parotid region during eating due to aberrant autonomic reinnervation of the sweat glands by the regenerating parasympathetic fibers from any residual parotid gland. Frey's syndrome may occur in as many as 25–60% of patients postoperatively. The risk for Frey's syndrome can be minimized first by complete and meticulous superficial parotidectomy. Second, by developing skin flaps of appropriate thickness, exposed apocrine glands of the skin are protected from ingrowth and stimulation by the severed branches of the auriculotemporal nerve and their parasympathetic stimulation during meals. There are numerous nonsurgical and surgical treatments for persistent Frey's syndrome following parotidectomy (see Chapter 5, Treatment of Frey's Syndrome).

Arterial Supply

The blood supply to the parotid gland is from branches of the *external carotid artery*, which courses superiorly from the carotid bifurcation and parallel to the mandible under the posterior belly of the digastric muscle. The artery then travels medial to the parotid gland and splits into two terminal branches. The *superficial temporal artery* runs superiorly from the superior portion of the parotid gland to the scalp within the superior pretragal region. The *maxillary artery* leaves the medial portion of the parotid and supplies the infratemporal fossa and the pterygopalatine fossa. During radical parotidectomy, this vessel must be controlled especially when marginal or segmental mandibulectomy is required. The *transverse facial artery* branches off the superficial temporal artery and runs anteriorly between the zygoma and parotid duct to supply the parotid gland, parotid duct, and the masseter muscle [10].

Venous Drainage

The *retromandibular vein*, formed by the union of the maxillary vein and the superficial temporal vein, runs through the parotid gland just deep to the facial nerve to join the external jugular vein. There is substantial variation in the surgical anatomy of the retromandibular vein, which may bifurcate into an anterior and posterior branch. The *anterior branch* can unite with the posterior facial vein, forming the common facial vein. The posterior facial vein lies immediately deep to the marginal mandibular branch of the facial nerve and is therefore often used as a landmark for identification of the nerve branch, especially at the antegonial notch of the mandible where the nerve dips inferiorly [3]. The *posterior branch of the retromandibular vein* may combine with the postauricular vein above the sternocleidomastoid muscle and drain into the external jugular vein.

Lymphatic Drainage

Contrary to the lymphatic drainage of the other salivary glands, there is a high density of lymph nodes within and around the parotid gland. The parotid is the only salivary gland with two nodal layers, both of which drain into the superficial and deep cervical lymph systems. Approximately 90% of the nodes are located in the superficial layer between the glandular tissue and its capsule. The parotid gland, external auditory canal, pinna, scalp, eyelids, and lacrimal glands are all drained by these superficial nodes. The deep layer of nodes drains the gland, external auditory canal, middle ear, nasopharynx, and soft palate [7].

Parapharyngeal Space

Tumors of the deep parotid lobe often extend medially into the parapharyngeal space (PPS). This space just posterior to the infratemporal fossa is shaped like an inverted pyramid. The greater cornu of the hyoid bone serves as the apex and the petrous bone of the skull base acts as the pyramidal base. The PPS is bound medially by the *lateral pharyngeal wall*, which consists of the superior constrictor muscles, the buccopharyngeal fascia and the tensor veli palatine. The ramus of the mandible and the medial pterygoid muscle make up the lateral border. The parapharyngeal space is bordered anteriorly by the pterygoid fascia and the pterygomandibular raphe. The posterior

border is lined by the carotid sheath and prevertebral fascia.

A line from the styloid process to the medial portion of the medial pterygoid plate divides the parapharyngeal space into two compartments. The *prestyloid compartment* contains the deep lobe of the parotid gland, minor salivary glands, as well as neurovascular structures, including the internal maxillary artery, ascending pharyngeal artery, the inferior alveolar nerve, the lingual nerve, and the auriculotemporal nerve. The *poststyloid compartment* contains the internal jugular vein, carotid artery and vagus nerve within the carotid sheath, as well as cranial nerves IX, X, XI, and XII and the cervical sympathetic chain. Neurogenic tumors or paragangliomas from the cervical sympathetics or cranial nerves can thus arise in this compartment [4].

Submandibular Gland

Anatomy

The submandibular gland (in older texts, this gland was sometimes referred to as “the submaxillary gland”) is the second largest major salivary gland and weighs 7–16 g (Fig. 1.3). The gland is located in the *submandibular triangle*, which has a superior boundary formed by the inferior edge of the mandible and inferior boundaries formed by the anterior and posterior bellies of the digastric muscle. Also lying within the triangle are the submandibular lymph nodes, facial artery and vein, mylohyoid muscle, and the lingual, hypoglossal, and mylohyoid nerves. Most of the submandibular gland lies posterolateral to the mylohyoid muscle. During neck dissection or submandibular gland excision, this mylohyoid muscle must be gently retracted anteriorly to expose the lingual nerve and submandibular ganglion. Often, smaller, tongue-like projections of the gland follow the duct, as it ascends toward the oral cavity, deep to the mylohyoid muscle [29]. However, these projections should be distinguished from the sublingual gland which lies superior to the mylohyoid muscle. (For more detail, see Chapter 21, Management of Tumors of the Submandibular and Sublingual Glands.)

Fascia

The middle layer of the deep cervical fascia encloses the submandibular gland. This fascia is clinically relevant be-

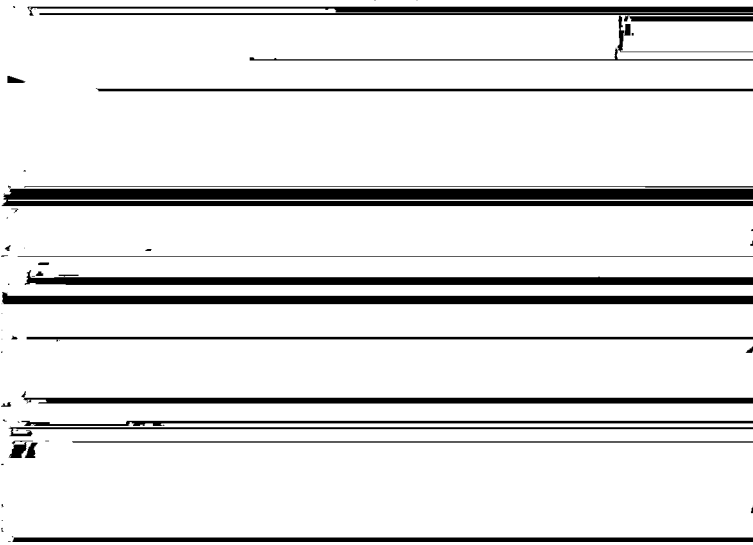


Fig. 1.3: The submandibular gland and important anatomic landmarks

cause the marginal mandibular branch of the facial nerve is superficial to it, and care must be taken to preserve the nerve during surgery in the submandibular region. Thus, division of the submandibular gland fascia, when oncologically appropriate, is a reliable method of preserving and protecting the marginal mandibular branch of the facial nerve during neck dissection and/or submandibular gland resection.

Wharton's Duct

The submandibular gland has both mucous and serous cells that empty into ductules, which in turn empty into the *submandibular duct*. The duct exits anteriorly from the sublingual aspect of the gland, coursing deep to the lingual nerve and medial to the sublingual gland. It eventually forms Wharton's duct between the hyoglossus and mylohyoid muscles on the genioglossus muscle. Wharton's duct, the main excretory duct of the submandibular gland, is approximately 4–5 cm long, running superior to the hypoglossal nerve while inferior to the lingual nerve. It empties lateral to the lingual frenulum through a papilla in the floor of the mouth behind the lower incisor tooth. The openings for the sublingual gland, or the *sublingual caruncles*, are located near the midline of the sublingual fold in the ventral tongue.

Neural Anatomy

Both the submandibular and the sublingual glands are innervated by the secretomotor fibers of the facial nerve (CN VII). Parasympathetic innervation from the *superior salivatory nucleus* in the pons passes through the *nervus intermedius* and into the internal auditory canal to join the facial nerve. The fibers are next conveyed by the *chorda tympani nerve* in the mastoid segment of CN VII, which travels through the middle ear and petrotympanic fissure to the infratemporal fossa. The *lingual nerve*, a branch of the marginal mandibular division of the fifth cranial nerve (CN V), then carries the presynaptic fibers to the *submandibular ganglion*. The postsynaptic nerve leaves the ganglion to innervate both the submandibular and sublingual glands to secrete watery saliva. As in the parotid gland, sympathetic innervation from the *superior cervical ganglion* accompanies the lingual artery to the submandibular tissue and causes glandular production of mucoid saliva instead [5].

The *lingual nerve* branches off the mandibular division of the trigeminal nerve (V_3) in the infratemporal fossa to supply general sensation and taste to the anterior two thirds of the tongue. The nerve courses laterally between the medial pterygoid muscle and ramus of the mandible and enters the oral cavity at the lower third molar to then travel across the hyoglossus along the

floor of the mouth in a submucosal plane. Beneath the mandible, a small motor nerve branches off and travels posteriorly from the lingual nerve to innervate the mylohyoid muscle. These fibers are usually sacrificed during surgical removal of the submandibular gland. Parasympathetic fibers are carried via the lingual nerve to the submandibular ganglion, and postsynaptic fibers exit along the course of the submandibular duct to innervate the gland.

The hypoglossal nerve (CN XII) supplies motor innervation to all extrinsic and intrinsic muscles of the tongue except for the palatoglossus muscle. From the hypoglossal canal at the base of the skull, the nerve is pulled inferiorly during embryonic development down into the neck by the occipital branch of the external carotid artery. From here, the hypoglossal nerve travels just deep to the posterior belly of the digastric muscle and common tendon until it reaches the submandibular triangle. Here CN XII lies deep in the triangle covered by a thin layer of fascia. Its location is anterior, deep and medial relative to the submandibular gland. Typically the nerve has a close relationship to the anterior belly of the digastric muscle. It then ascends anterior to the lingual nerve and its genu deep to the mylohyoid muscle. Extreme care should be taken to preserve this important nerve during head and neck surgery.

Arterial Supply

Both the submandibular and sublingual glands are supplied by the *submental* and *sublingual arteries*, branches of the lingual and facial arteries. The *facial artery*, the tortuous branch of the external carotid artery, is the main arterial blood supply of the submandibular gland. It runs medial to the posterior belly of the digastric muscle and then hooks over to course superiorly deep to the gland. The artery exits at the superior border of the gland and the inferior aspect of the mandible known as the *facial notch*. It then runs superiorly and adjacent to the inferior branches of the facial nerve into the face. During submandibular gland resection, the artery must be sacrificed twice, first at the inferior border of the mandible and again just superior to the posterior belly of the digastric muscle. The *lingual artery* branches inferior to or with the facial artery off the external carotid artery. It runs deep to the digastric muscle along the lateral surface of the middle constrictor and then courses anterior and medial to the hyoglossus muscle.

Venous Drainage

The submandibular gland is mainly drained by the *anterior facial vein*, which is in close approximation to the facial artery as it runs inferiorly and posteriorly from the face to the inferior aspect of the mandible. Because it lies just deep to the marginal mandibular division of the facial nerve, ligation and superior retraction of the anterior facial vein can help preserve this branch of the facial nerve during submandibular gland surgery. It forms extensive anastomoses with the infraorbital and superior ophthalmic veins. The *common facial vein* is formed by the union of the anterior and posterior facial veins over the middle aspect of the gland. The common facial vein then courses lateral to the gland and exits the submandibular triangle to join the internal jugular vein.

Lymphatic Drainage

The prevascular and postvascular lymph nodes draining the submandibular gland are located between the gland and its fascia, but are not embedded in the glandular tissue. They lie in close approximation to the facial artery and vein at the superior aspect of the gland and empty into the deep cervical and jugular chains. These nodes are frequently associated with cancers in the oral cavity, especially in the buccal mucosa and the floor of the mouth. Thus, when ligating the facial artery and its associated plexus of veins, greater care must be taken not only to resect all associated lymphoadipose tissue, but also to preserve the marginal mandibular branch of the facial nerve, which runs in close proximity to these structures.

Sublingual Gland

The smallest of the major salivary glands is the sublingual gland, weighing 2–4 g. Consisting mainly of mucous acinar cells, it lies as a flat structure in a submucosal plane within the anterior floor of the mouth, superior to the mylohyoid muscle and deep to the sublingual folds opposite the lingual frenulum [11]. Lateral to it are the mandible and genioglossus muscle. There is no true fascial capsule surrounding the gland, which is instead covered by oral mucosa on its superior aspect. Several ducts (*of Rivinus*) from the superior portion of the sublingual gland either secrete directly into the floor of mouth, or empty into *Bartholin's duct* that then continues into Wharton's duct.

Both the sympathetic and parasympathetic nervous systems innervate the sublingual gland. The presynaptic parasympathetic (secretomotor) fibers of the *facial nerve* are carried by the chorda tympani nerve to synapse in the submandibular ganglion. Postganglionic fibers then exit the *submandibular ganglion* and join the lingual nerve to supply the sublingual gland. Sympathetic nerves innervating the gland travel from the *cervical ganglion* with the facial artery [5].

Blood is supplied to the sublingual gland by the *submental* and *sublingual arteries*, branches of the lingual and facial arteries, respectively. The venous drainage parallels the corresponding arterial supply. The sublingual gland is mainly drained by the submandibular lymph nodes.

Ranulas are cysts or mucoceles of the sublingual gland, and they can exist either simply within the sublingual space or plunging posteriorly to the mylohyoid muscle into the neck. A simple ranula will most commonly present as a bluish, nontender mass in the floor of the mouth and may either be a retention cyst or an extravasation pseudocyst. A plunging ranula will present as a soft, painless cervical mass and is always an extravasation pseudocyst (see Chapter 10, Management of Mucoceles and Ranula).

Minor Salivary Glands

About 600 to 1,000 minor salivary glands, ranging in size from 1 to 5 mm, line the oral cavity and oropharynx. The greatest number of these glands are in the lips, tongue, buccal mucosa, and palate, although they can also be found along the tonsils, supraglottis, and paranasal sinuses. Each gland has a single duct which secretes, directly into the oral cavity, saliva which can be either serous, mucous, or mixed.

Postganglionic parasympathetic innervation arises mainly from the *lingual nerve*. The palatine nerves, however, exit the sphenopalatine ganglion to innervate the superior palatal glands. The oral cavity region itself determines the blood supply and venous and lymphatic drainage of the glands. Any of these sites can also be the source of glandular tumors [11].

Histology

All glands in general are derived from epithelial cells and consist of *parenchyma* (the secretory unit and associated

ducts) and *stroma* (the surrounding connective tissue that penetrates and divides the gland into lobules). Secretory products are synthesized intracellularly and subsequently released from secretory granules by various mechanisms. Glands are usually classified into two main groups. *Endocrine glands* contain no ducts, and the secretory products are released directly into the bloodstream or lymphatic system. In contrast, *exocrine glands* secrete their products through a duct system that connects them to the adjacent external or internal epithelial surfaces. Salivary glands are classified as exocrine glands that secrete saliva through ducts from a flask-like, blind-ended secretory structure called the *salivary acinus*.

The acinus itself can be divided into three main types. *Serous acini* in salivary glands are roughly spherical and release via exocytosis a watery protein secretion that is minimally glycosylated or nonglycosylated from secretory (or zymogen) granules. The acinar cells comprising the acinus are pyramidal, with basally located nuclei surrounded by dense cytoplasm and secretory granules that are most abundant in the apex. *Mucinous acini* store a viscous, slimy glycoprotein (*mucin*) within secretory granules that become hydrated when released to form *mucus*. Mucinous acinar cells are commonly simple columnar cells with flattened, basally situated nuclei and water-soluble granules that make the intracellular cytoplasm appear clear. *Mixed*, or *seromucous*, *acini* contain components of both types, but one type of secretory unit may dominate. Mixed secretory units are commonly observed as serous *demilunes* (or half-moons) capping mucinous acini.

Between the epithelial cells and basal lamina of the acinus, flat *myoepithelial cells* (or basket cells) form a latticework and possess cytoplasmic filaments on their basal side to aid in contraction, and thus forced secretion, of the acinus. Myoepithelial cells are also observed around intercalated ducts, but here they are more spindle shaped [16].

Electrolyte modification and transportation of saliva are carried out by the different segments of the salivary gland's duct system (Fig. 1.4). The acini first secrete through small canaliculi into the intercalated ducts, which in turn empty into striated ducts within the glandular lobule. The intercalated duct is comprised of an irregular myoepithelial cell layer lined with squamous or low cuboidal epithelium. Bicarbonate is secreted into while chloride is absorbed from the acinar product within the intercalated duct segment. Striated ducts have distinguishing basal striations due to membrane invagination and mitochondria and are lined by a simple columnar




Fig. 1.4: Functional histology of the salivon

epithelium. These ducts are involved with the reabsorption of sodium from the primary secretion and the concomitant secretion of potassium into the product. The abundant presence of mitochondria is necessary for the ducts' transport of both water and electrolytes. The acinus, intercalated duct, and striated duct are collectively known as a single secretory unit called a *salivon* [15].

The next segment of the duct system is marked by the appearance of the interlobular excretory ducts within the connective tissue of the glandular septae. The epithelial lining is comprised of sparse goblet cells interspersed among the pseudostratified columnar cells. As the diameter of the duct increases, the composition of the epithelial lining transitions to stratified columnar, and then to nonkeratinized stratified squamous cells, within the oral cavity [16].

The arterial blood flow received by the salivary glands is high relative to their weight and is opposite the flow of saliva within the duct system. The acini and ductules are supplied by separate parallel capillary beds. The high permeability of these vessels permits rapid transfer of molecules across their basement membranes. The high volume of saliva produced by the salivary glands relative to their weight is partly due to the high blood flow rate through the glandular tissue.

The serous acini that make up the *parotid gland* are roughly spherical, and they are comprised of pyramidal epithelial cells surrounded by a distinct basement membrane. Merocrine secretion by the epithelial cells releases a secretory mixture containing amylase, lysozyme, an IgA secretory piece, and lactoferrin into the central lumen of the acinus. The main excretory duct is also known as *Stensen's duct* and empties into the oral cavity opposite the second upper molar tooth.

The *submandibular gland* is classified as a mixed gland that is predominantly serous with tubular acini. The majority of acinar cells are serous with very granular eosinophilic cytoplasm. Only approximately 10% of the acini are mucinous, with large, triangular acinar cells containing central nuclei and clear cytoplasmic mucin vacuoles ranging in size. The mucinous cells are capped by demilunes, which are crescent-shaped formations of serous cells. The intercalated ducts of the submandibular gland are longer than those of the parotid gland, while striated ducts are shorter by comparison. *Wharton's duct* serves as the main excretory duct and empties into the floor of the mouth.

Like the submandibular gland, the *sublingual gland* has mixed acini with observable serous demilunes within the glandular tissue. Unlike the submandibular gland, however, the sublingual gland is predominantly

mucinous. The main duct empties into the submandibular duct and is also known as *Bartholin's duct*. Several smaller ducts (*of Rivinus*) also directly secrete into the floor of the mouth.

The *minor salivary glands* are found throughout the oral cavity, with the greatest density in the buccal and labial mucosa, the posterior hard palate, and tongue base. They are not as often observed, however, in the attached gingiva and closely associated anterior hard palatal mucosa. The majority of these glands are either mucinous or seromucinous, except for the serous *Ebner's glands* on the posterior aspect of the tongue. These deep posterior salivary glands of the tongue are also marked by the presence of ciliated cells, especially within the distal segments of the excretory ducts. The minor salivary gland duct system is simpler than that of the major salivary glands, where the intercalated ducts are longer and the striated ducts are either less developed or not present [15].

Physiology of Salivary Glands

Saliva production, the main function of the salivary glands, is crucial in the processes of digestion, lubrication, and protection in the body. Saliva is actively produced in high volumes relative to the mass of the salivary glands, and it is almost completely controlled extrinsically by both the parasympathetic and sympathetic divisions of the autonomic nervous system.

Saliva plays a crucial role in the digestion of carbohydrates and fats through two main enzymes. *Ptyalin* is an α -amylase in saliva that cleaves the internal α -1,4-glycosidic bonds of starches to yield maltose, maltotriose, and α -limit dextrins. This enzyme functions at an optimal pH of 7, but rapidly denatures when exposed to a pH less than 4, such as when in contact with the acidic secretions of the stomach. Up to 75% of the carbohydrate content in a meal, however, is broken down by the enzyme within the stomach. This is due to the fact that a significant portion of an ingested meal remains unmixed within the oral region, and thus there is a delay in the mixture of gastric juices with the food bolus. Starch digestion is not slowed in the absence of ptyalin because pancreatic amylase is identical to salivary amylase and is thus able to break down all carbohydrates when in the small intestine. The salivary glands of the tongue produce *lingual lipase*, which functions to break down triglycerides. Unlike ptyalin, this enzyme is functional within the acidic stomach and proximal duodenum because it is optimally active at a low pH.

Saliva also serves to dissolve and transport food particles away from taste buds to increase taste sensitivity.

The mucus constituent of saliva facilitates the lubrication of food particles during the act of chewing, which serves to mix the food with saliva. Lubrication eases the processes of swallowing and of the bolus traveling down the esophagus. Salivary lubrication is also crucial for speech.

The antibacterial properties of saliva are due to its many protective organic constituents. The binding glycoprotein for immunoglobulin A (IgA), known as the *secretory piece*, forms a complex with IgA that is immunologically active against viruses and bacteria. *Lysozyme* causes bacterial agglutination and autolysin activation to degrade bacterial cell walls. *Lactoferrin* inhibits the growth of bacteria that need iron by chelating with the element. Saliva also serves as a protective buffer for the mouth by diluting harmful substances and lowering the temperature of solutions that are too hot. It washes out foul-tasting substances from the mouth and neutralizes gastric juice to protect the oral cavity and esophagus. *Xerostomia*, or dry mouth, due to lack of salivation, can lead to chronic buccal mucosal infections or dental caries.

Comprised of both inorganic and organic compounds, saliva is distinguished by its high volume compared to salivary gland weight, high potassium concentration, and low osmolarity (Fig. 1.5). The large relative volume of saliva production is due to its high secretion rate, which can go up to 1 ml per gram of salivary gland per minute. Saliva is mostly hypotonic to plasma, but its osmolarity increases with increasing rate of secretion, and at its highest rate saliva approaches isotonicity. The concentration of electrolytes in saliva also changes with varying secretion rates.

Within the salivary gland, potassium (K^+) concentration is always high while sodium (Na^+) concentration is low compared to that found in plasma. With increasing flow rates, however, Na^+ concentration increases, while K^+ concentration initially decreases slightly and then levels off to a constant level. Chloride (Cl^-) concentrations follow the same general pattern as Na^+ concentrations. In other words, Na^+ and Cl^- are generally secreted and then slowly reabsorbed along the course of the salivary system, from acinus to duct. The salivary concentration of bicarbonate (HCO_3^-) is hypertonic compared to in plasma except at lower rates of secretion.

Initially within the salivon, the acini first produce a primary secretion that is relatively isotonic to plasma. As the saliva travels through the ducts, Na^+ and Cl^- are




Fig. 1.5: Electrolyte secretion by the acinar and ductal cells

reabsorbed, while K^+ and HCO_3^- are secreted into the fluid. Less time is available for the movement of these electrolytes when the flow rate of saliva is higher. At high flow rates, therefore, plasma and saliva are similar in concentration. At lower secretion rates, K^+ concentration is higher in the saliva, while Na^+ and Cl^- concentrations are significantly lower. Bicarbonate concentrates remains fairly hypertonic relative to in plasma even with higher flow rates due to its secretory stimulation by most salivary gland agonists. Saliva is mostly hypotonic to plasma due to the fact that reabsorption of Na^+ and Cl^- is greater than the secretion of K^+ and HCO_3^- within the salivary ducts.

Several organic compounds present in saliva have already been discussed: α -amylase, lingual lipase, mucus, lysozymes, glycoproteins, lactoferrin, and the IgA secretory piece. Saliva is also comprised of the organic *blood group antigens* A, B, AB, and O. *Kallikrein* is secreted by the salivary glands during increased metabolic activity.

Kallikrein enzymatically converts plasma protein into bradykinin, a vasodilator, in order to increase blood flow to the glands. Saliva contains approximately one tenth the total amount of protein as that found in plasma.

The secretion, blood flow, and growth of salivary glands are mostly controlled by both branches of the autonomic nervous system. Even though the parasympathetic nervous system has more influence on the secretion rate of the salivary glands than the sympathetic system, secretion is *stimulated* by both branches.

Parasympathetic innervation of the major salivary glands follows branches of the facial and glossopharyngeal nerves. Parasympathetic stimulation activates both acinar activity and ductal transport mechanisms, leading to glandular vasodilation as well as myoepithelial cell contraction. *Acetylcholine* (ACh) serves as the parasympathetic neurotransmitter that acts on the muscarinic receptors of the salivary glands. The subsequent formation of inositol trisphosphate leads to increased Ca^{2+} concen-

trations within the cell, released from either intracellular Ca^{2+} stores or from the plasma. This second messenger significantly effects salivary volume secretion. Glandular secretion is sustained by *acetylcholinesterases*, which inhibit the breakdown of ACh. The muscarinic antagonist *atropine*, however, decreases salivation by competing with ACh for the salivary receptor site.

The sympathetic supply to the salivary gland is mainly from the thoracic spinal nerves of the superior cervical ganglion. Like parasympathetic innervation, myoepithelial cell contraction also results. Changes in blood flow, however, are biphasic: vasoconstriction due to α -adrenergic receptor activation is followed by vasodilation due to buildup of vasodilator metabolites. Binding of the neurotransmitter *norepinephrine* to α -adrenergic receptor results in formation of 3',5'-cyclic adenosine monophosphate (cAMP), which then leads to phosphorylation of various proteins and activation of different enzymes. Increases in cAMP result in increased salivary enzyme and mucus content.

Within saliva, K^+ concentrations increase while Na^+ concentrations decrease in the presence of antidiuretic hormone (ADH) or aldosterone. Unlike other digestive glands, however, these two hormones do not affect salivary gland secretion rate.

About 1 l of saliva is secreted by a normal adult each day. During unstimulated salivation, 69% of saliva is contributed by the submandibular glands, 26% by the parotid, and 5% by the sublingual glands. The relative amounts supplied by the parotid and submandibular glands, however, are switched during stimulation, where two thirds of secretion is then from the parotid gland. Of total flow, 7–8% is due to the minor salivary glands regardless of stimulation. The presence of food in the mouth, the act of chewing, and nausea all stimulate salivation, while sleep, fatigue, dehydration, and fear inhibit it. Salivary secretion rates are not dependent on age, and flow rates remain constant despite the degeneration of acinar cells during the aging process. Medication side effects or systemic disease are more likely to be responsible for hypofunction of salivary glands in elderly patients [15, 17].

Evaluation of the Salivary Glands

Symptoms indicative of salivary gland disorders are limited in number and generally nonspecific. Patients usually complain of swelling, pain, xerostomia, foul taste, and sometimes *sialorrhea*, or excessive salivation. Despite

the prevalence of modern technology in the identification of salivary gland disorders, a detailed history and thorough physical examination still play significant roles in the clinical diagnosis of the patient, and great care should be taken during these initial steps of evaluation.

History

When taking a patient's history, the practiced skills of attentive listening and patience are required for subsequent diagnosis and proper treatment most fitting to the patient's expectations and needs. The medical profile of the patient can provide helpful clues to the current condition of the salivary glands, for dysfunction of these glands is often associated with certain systemic disorders such as diabetes mellitus, arteriosclerosis, hormonal imbalances, and neurologic disorders. Either xerostomia or sialorrhea, for instance, may be due to factors affecting the medullary salivary center, autonomic outflow pathway, salivary gland function itself, or fluid and electrolyte balance.

The factors of age group and gender are also important, for several diseases are often related to age or gender. The autoimmune disorder known as *Sjögren's syndrome*, for example, is common in menopausal women, while *mumps*, parotid swelling due to paramyxoviral infection, usually occurs in children between the ages of 4 and 10 years.

Drug history of the patient should also be considered, for salivary function is often affected by drug usage. Xerostomia is often due to the use of diuretics and other antihypertensive drugs [9, 18].

A careful dietary and nutrition history should be obtained. Patients who are dehydrated chronically from bulimia or anorexia or during chemotherapy are at risk for parotitis. Swelling and pain during meals followed by a reduction in symptoms after meals may indicate partial ductal stenosis.

Xerostomia is a debilitating consequence of radiation therapy to the head and neck and a history of prior radiation should be sought.

Physical Examination

The superficial location of the salivary glands allows thorough inspection and palpation for a complete physical examination. Initial inspection involves the careful examination of the head and neck regions, both intraorally

and extraorally, and should be carried out in a systematic way so as to not miss any crucial signs.

During the initial *extraoral inspection*, the patient should stand three to four feet away and directly facing in front of the examiner. The examiner should inspect symmetry, color, possible pulsation and discharging of sinuses on both sides of the patient. Enlargement of major or minor salivary glands, most commonly the parotid or submandibular, may occur on one or both sides. *Parotitis* typically presents as preauricular swelling, but may not be visible if deep in the parotid tail or within the substance of the gland. *Submandibular swelling* presents just medial and inferior to the angle of the mandible. Salivary gland swelling can generally be differentiated from those of lymphatic origin as being single, larger, and smoother, but the two types are often easily confused. Significant neurologic deficits should be examined as well. Facial nerve paralysis in conjunction with a parotid mass, for example, should remind us of a *malignant* parotid neoplasm, although it does occur rarely with benign neoplasms as well.

In addition to signs of possible asymmetry, discoloration, or pulsation, *intraoral inspection* also includes assessment of the duct orifices and possible obstructions. The proper lighting with a headlight should always be used when inspecting within the oral cavity and pharynx. The openings of Stensen's and Wharton's ducts can be inspected intraorally opposite the second upper molar and at the root of the tongue, respectively. Drying off the mucosa around the ducts with an air blower and then pressing on the corresponding glands will allow the examiner to assess the flow or lack of flow of saliva. Sialolithiasis can sometimes be found by careful intraoral palpation. Dental hygiene and the presence of periodontal disease should also be noted since deficient oral maintenance is a major predisposing factor to various infectious diseases.

Size, consistency, and other qualities of the salivary glands and associated masses can be evaluated through extraoral and intraoral palpation. Bimanual assessment should be performed whenever possible with the palmar aspect of the fingertips.

During *extraoral palpation* of the face and neck, the patient's head is inclined forward to maximally expose the parotid and submandibular gland regions. The examiner may stand in front of or behind the patient. It should be noted that observable salivary or lymphatic gland swellings do not rise with swallowing, while swellings associated with the thyroid gland and larynx do elevate.

Finally, bimanual palpation (extraoral with one hand, introral with the other) must be performed to exam-

ine the parotid and submandibular glands. One or two gloved fingers should be inserted within the oral cavity to palpate the glands and main excretory ducts internally, while using the other hand to externally support the head and neck. By rolling the hands over the glands both internally and externally, subtle mass lesions can be identified. In the submandibular gland, lymph nodes extrinsic to the gland can often be distinguished from pathology within the gland itself using this technique. The neck should then also be carefully examined for lymphadenopathy.

Finally, a careful survey of minor salivary gland tissue should be performed, especially in the anterior labial, buccal, and posterior palatal mucosa. Increased salivation from the duct orifices due to pressure externally applied to the glands may indicate inflammation [9, 18]. Finally, rare clinical entities, such as hemangiomas and other vascular anomalies, may be identified by auscultation.

Radiologic and Endoscopic Examination of the Salivary Glands

Although a thorough history and complete physical examination are crucial steps in the diagnosis and eventual treatment of any salivary gland disorder, patients occasionally provide little more than vague complaints of pain and/or swelling. For patients with these unclear symptoms and no physical signs, radiographic diagnostic studies, such as sialography, plain-film radiography, computed tomography, and magnetic resonance imaging, can play an important role in clarifying the etiology of such nonspecific symptoms. For patients with known disease, imaging can assist in treatment selection and planning. This final section will provide a brief introduction to these various techniques, which will then be covered in greater detail in subsequent chapters.

Sialography relies on the injection of contrast medium into glandular ducts so that the pathway of salivary flow can be visualized by plain-film radiographs. Correct exposure and positioning is achieved by taking preliminary plain radiographs prior to the injection of a radiopaque medium [9]. The most common indication for sialography is the presence of a salivary calculus, which is a deposit of mostly calcium salts that can block flow of saliva and cause pain, swelling, and inflammation or lead to infection. Patients with calculi usually complain of a recurrent and acute onset of pain and swelling during eating. Often, sialographic examination is unnecessary if the preliminary radiographs detect the calculus before-

hand. Other indications for sialography include gradual or chronic glandular enlargement (which can be due to sarcoidosis, infection, sialosis, Sjögren's syndrome, benign lymphoepithelial lesion, or a neoplasm), a clinically palpable mass in one of the glandular regions (possible tumor, cyst, or focal inflammation), recurrent sialadenitis, or dryness of the mouth.

Although conventional sialography can be clinically useful in the diagnosis and the determination of treatment for various salivary disorders, its effectiveness remains arguable while its rate of usage is highly variable [25, 30]. This method should not be performed when the patient has an acute salivary gland infection, has a known sensitivity to iodine-containing compounds, or is anticipating thyroid function tests. Thus, other methods of radiographic diagnosis are currently preferred and have largely replaced sialographic examination.

Computed tomography (CT) is now more widely used to assess the parotid and submandibular glands. The advantage of CT imaging is the two-dimensional view of the salivary glands, which can elucidate relationships to adjacent vital structures as well as to assess the draining cervical lymphatics. The parotid gland has low attenuation due to its high fat content and is therefore easily discernible by CT scanning. The submandibular gland has a lower fat content and higher density compared to the parotid gland and thus has a much higher attenuation, although extrinsic and intrinsic mass differentiation is easier to evaluate. Although stones can be identified, salivary gland inflammation is not generally an indication for CT. While CT is often utilized as a primary screening tool for the detection of parotid and submandibular gland abnormalities, in difficult cases, a higher-sensitivity approach using both CT and sialography (CT-sialography) can be used [24]. Differences between intrinsic and extrinsic parotid gland masses, however, are often difficult to assess especially when present in the parapharyngeal space [27].

Magnetic resonance imaging (MRI) is more often used for assessment of parapharyngeal space abnormalities. MRI provides better contrast resolution, exposes the patient to less harmful radiation, and yields detailed images on several different planes without patient repositioning. This technique therefore is preferred in the evaluation of parapharyngeal space masses, especially in discriminating between deep lobe parotid tumors and other pathology, such as schwannoma and/or glomus vagale. MRI, however, is inferior to CT scanning for the detection of calcifications and early bone erosion. Chronic inflammation of the salivary glands and calculi are not indications for MRI.

Sialendoscopy is a minimally invasive technique that inspects the salivary glands using narrow-diameter, rigid fiberoptic endoscopes [20]. Endoscopic visualization of ductal and glandular pathology provides an excellent alternative to the indirect diagnostic techniques described above. As such, sialendoscopy has opened up a new frontier for both evaluation and treatment of salivary gland disease [21]. Lacrimal probes are used to gently dilate the ductal orifice and then the endoscope is introduced under direct visualization. During lavage of the glandular duct of interest, direct inspection of the duct and hilum of the gland is performed. Thus, in one setting, at the time of diagnosis, treatment and therapy for benign lesions can be performed (see Chapter 6, Sialendoscopy). Through a CO₂-laser papillotomy, sialolithectomy can be easily performed [21]. Pharmacotherapy and laser-ablation can also be performed. Sialendoscopy has also been shown to have a significantly low complication rate and is generally well-tolerated [31]. This relatively new technique has shown much promise in the diagnosis and treatment of chronic obstructive sialadenitis (COS), sialolithiasis, and other obstructive diseases of the salivary glands.

Take Home Messages

- ▶ Salivary gland development is the result of branching morphogenesis. Molecular biology is beginning to unravel signaling pathways implicated in both craniofacial development and salivary gland histogenesis, including the sonic hedgehog (Shh) and the fibroblast growth factor family.
- ▶ Human saliva is not only important for lubrication in the oral cavity, but plays a crucial role in digestive and protective processes.
- ▶ Both visual inspection with optimal lighting and bimanual palpation is crucial in the precise physical examination of the major and minor salivary glands.
- ▶ Sialendoscopy is a novel modality for diagnostic evaluation as well as therapeutic intervention for disorders of the salivary glands.

References

1. Arey LB (1974) *Developmental anatomy; a textbook and laboratory manual of embryology*. Revised 7th ed. W.B. Saunders, Inc., Philadelphia
2. Bernfield M, Banerjee S, Cohn R (1972) Dependence of salivary epithelial morphology and branching morphogenesis upon acid mucopolysaccharide-protein (proteoglycan) at the epithelial surface. *J Cell Biol* 52:674–689
3. Bhattacharyya N, Varvares M (1999) Anomalous relationship of the facial nerve and the retromandibular vein: a case report. *J Oral Maxillofac Surg* 57:75–76
4. Carrau RL, Johnson JT, Myers EN (1997) Management of tumors of the parapharyngeal space. *Oncology (Williston Park)* 11:633–640; discussion 640, 642
5. Davis RA, Anson BJ, Budinger JM, et al. (1956) Surgical anatomy of the facial nerve and parotid gland based upon a study of 350 cervicofacial halves. *Surg Gynecol Obstet* 102: 385–412
6. Frommer J (1977) The human accessory parotid gland: its incidence, nature, and significance. *Oral Surg Oral Med Oral Pathol* 43: 671–676
7. Garatea-Crelgo J, Gay-Escoda C, Bermejo B, et al. (1993) Morphological study of the parotid lymph nodes. *J Cranio-maxillofac Surg* 21:207–209
8. Gibson MH (1983) The prenatal human submandibular gland: a histological, histochemical and ultrastructural study. *Anat Anz* 153:91–105
9. Graamans K, von der Akker HP (1991) History and physical examination. In: Graamans AK (ed) *Diagnosis of Salivary Gland Disorders*. Kluwer Academic Publishers, Dordrecht, Germany, pp 1-3
10. Grant J (1972) *An Atlas of Anatomy*, Sixth edn. Williams & Wilkins, Baltimore
11. Hollinshead WH (1982) *Anatomy for Surgeons: Volume I, The Head and Neck*, Third ed. J.B. Lippincott Company, Philadelphia
12. Jaskoll T, Melnick M (1999) Submandibular gland morphogenesis: stage-specific expression of TGF- α /EGF, IGF, TGF- β , TNF, and IL-6 signal transduction in normal embryonic mice and the phenotypic effects of TGF- β 2, TGF- β 3, and EGF-r null mutations. *Anat Rec* 256:252–268
13. Jaskoll T, Leo T, Witcher D, et al. (2004) Sonic hedgehog signaling plays an essential role during embryonic salivary gland epithelial branching morphogenesis. *Dev Dyn* 229: 722–732
14. Johns M (1977) The salivary glands: anatomy & embryology. *Otolaryngol Clin North Am* 10:261
15. Johnson LR (ed) (2003) *Secretion*. Elsevier, Amsterdam
16. Junqueira L, Carneiro J (2003) *Basic Histology: Text & Atlas*, Tenth edn. McGraw-Hill, New York
17. Kontis TC, Johns ME (2001) *Anatomy and Physiology of the Salivary Glands*. In: Bailey BJ (ed) *Head and Neck Surgery – Otolaryngology*. Lippincott Williams & Wilkins, Philadelphia
18. Mason D, Chisholm D (1975) *Salivary Glands in Health and Disease*. WB Saunders, London
19. Myers EN, Conley J (1970) Gustatory sweating after radical neck dissection. *Arch Otolaryngol* 91:534–542
20. Nahlieli O, Baruchin AM (1997) Sialoendoscopy: three years' experience as a diagnostic and treatment modality. *J Oral Maxillofac Surg* 55:912–918; discussion 919–920
21. Nahlieli O, Baruchin AM (2000) Long-term experience with endoscopic diagnosis and treatment of salivary gland inflammatory diseases. *Laryngoscope* 110:988–993
22. Orabi AA, Riad MA, O'Regan MB (2002) Stylomandibular tenotomy in the transcervical removal of large benign parapharyngeal tumours. *Br J Oral Maxillofac Surg* 40: 313–316
23. Pogrel M, Schmidt B, Ammar A (1996) The relationship of the buccal branch of the facial nerve to the parotid duct. *J Oral Maxillofac Surg* 54:71–73
24. Quinn HJ Jr. (1976) Symposium: management of tumors of the parotid gland. II. Diagnosis of parotid gland swelling. *Laryngoscope* 86:22–24
25. Rabinov K, Weber AL (1985) *Radiology of the Salivary Glands*. G.K. Hall Medical Publishers, Boston
26. Roark DT, Sessions RB, Alford BR (1975) Frey's syndrome—a technical remedy. *Ann Otol Rhinol Laryngol* 84:734–739
27. Som PM, Biller HF (1979) The combined computerized tomography-sialogram. A technique to differentiate deep lobe parotid tumors from extraparotid pharyngomaxillary space tumors. *Ann Otol Rhinol Laryngol* 88:590–595
28. Uehara T (2006) Localization of FGF-6 and FGFR-4 during prenatal and early postnatal development of the mouse sublingual gland. *J Oral Sci* 48:9–14
29. Woodburne RT, Burkel WE (1988) *Essentials of Human Anatomy*, Eighth edn. Oxford University Press, New York, Oxford
30. Yune H (1977) Sialography and dacrocystography. In: Miller R, Skucas J (eds) *Radiographic contrast agents*. University Park Press, Baltimore, pp 485–492
31. Ziegler CM, Hedemark A, Brevik B, et al. (2003) Endoscopy as minimal invasive routine treatment for sialolithiasis. *Acta Odontol Scand* 61:137–140